A 55-year-old male presenting with an orbital mass

Reported by Victor Brochu & Dr. R Michel; RVH PATH; Reviewed by Dr.Marc Pusztaszeri | 6 Jun 2019

Clinical

The patient is a 55-year-old male smoker known for dyslipidemia who presented with left eye erythema/irritation and blurred vision. CT scan of the orbit revealed a 3.6 cm left inferior orbital mass causing significant proptosis of the left eye (Figure 1). The patient underwent surgical resection of the tumor via orbitotomy.

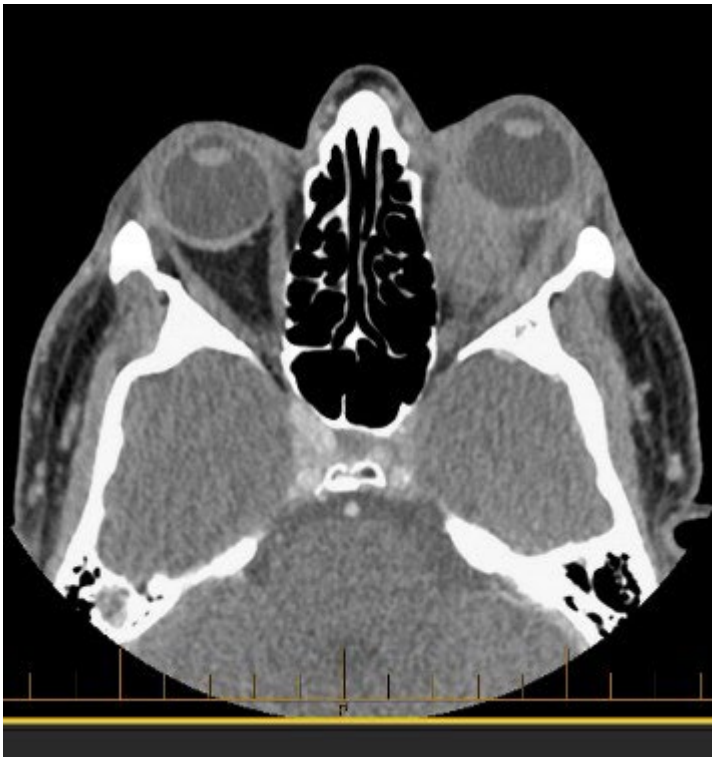

Fig1: Orbital CT scan, left inferior orbital mass with significant left eye proptosis.

Histology

The tumor is composed of a diffuse proliferation of monomorphic, medium-sized, lymphocytes, with a mild-to-moderate amount of cytoplasm (Figure 2). The tumor also shows abundant mitoses and apoptotic debris (Figure 3).
The tumor contains a prominent reactive/inflammatory component, with abundant histiocytes,

lymphocytes and plasma cells (Figure 4). Of note, one of the fragments can be divided into a reactive part and a tumoral part (Figure 5), which is helpful for the interpretation of immunohistochemistry.

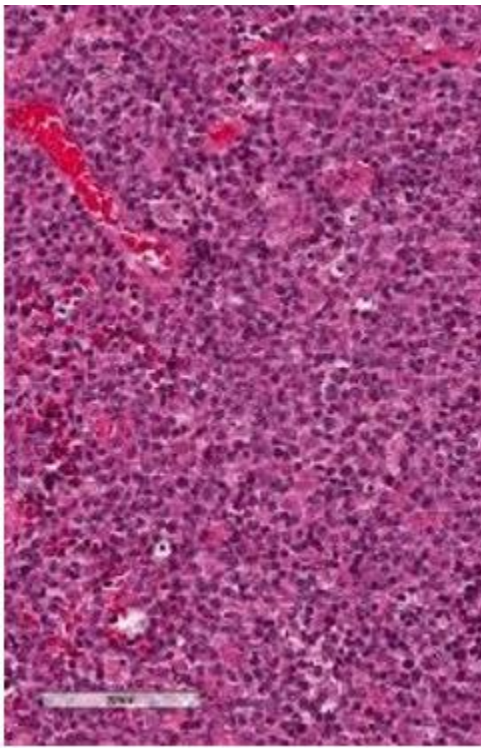

Figure 2: Tumor is composed of a diffuse proliferation of monomorphic medium-sized lymphocytes. H&E, 200x.

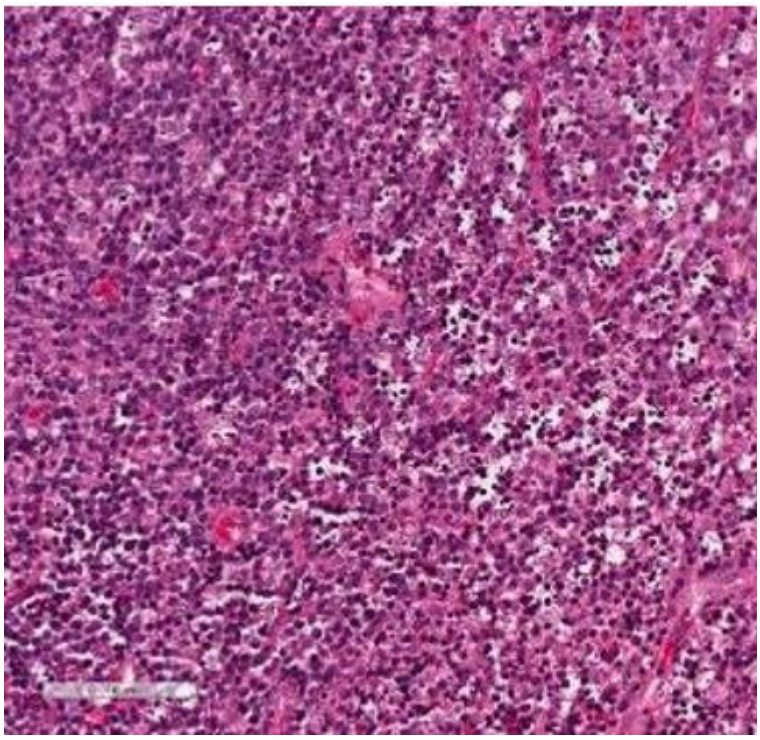

Figure 3: Abundant tumoral apoptotic debris. H&E, 200x.

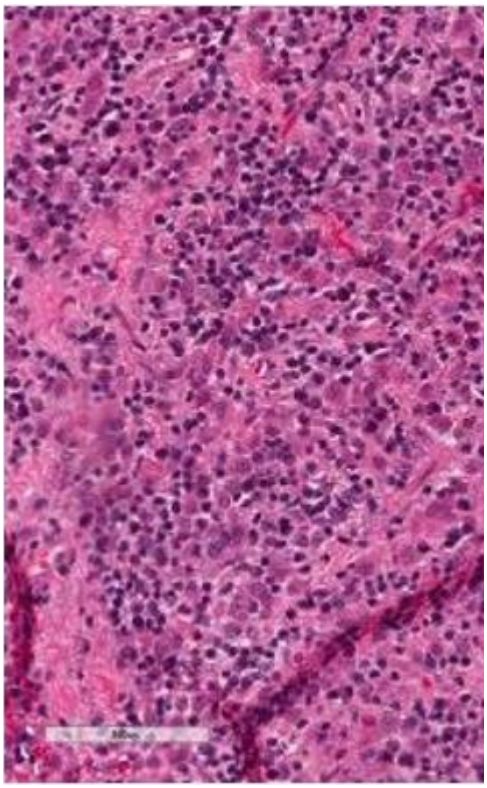

Figure 4: Prominent mixed reactive inflammatory infiltrate. H&E, 200x.

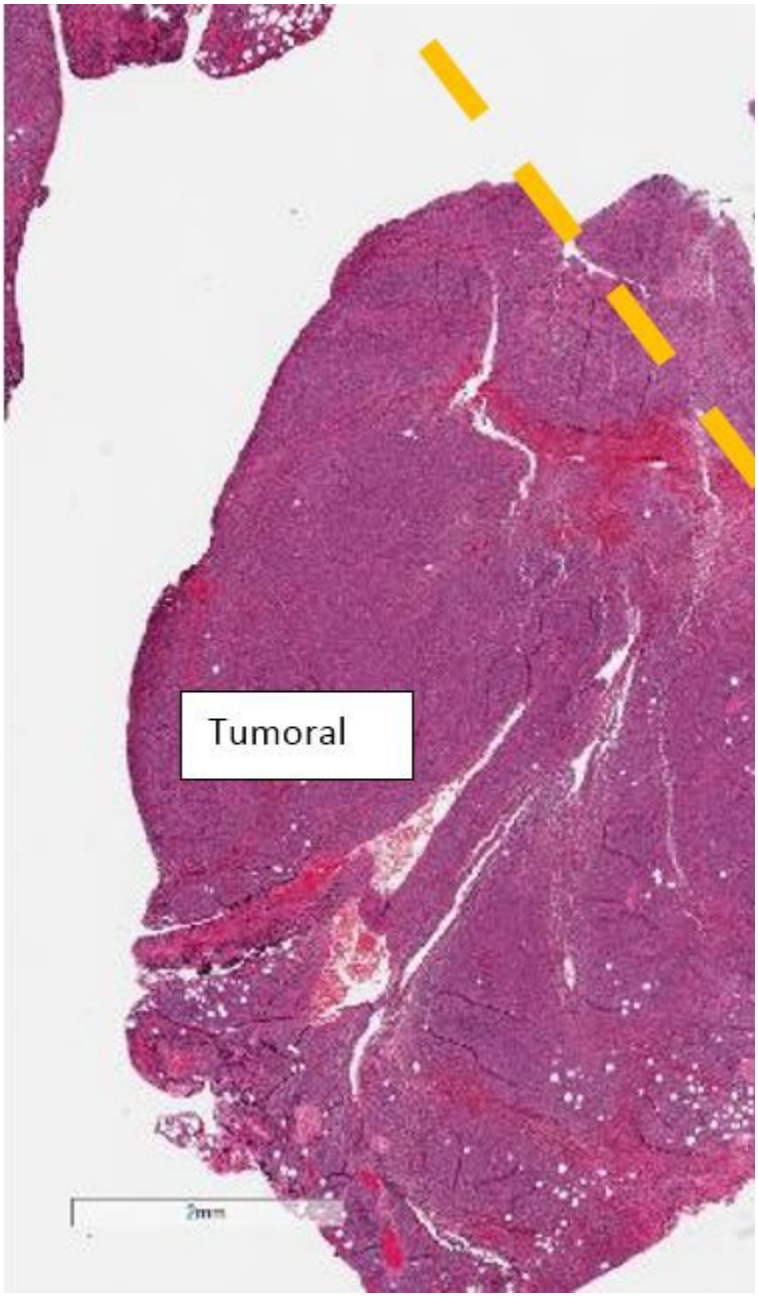

Figure 5: Orbital mass resection. The specimen can be divided in reactive (right) and tumoral (left) parts. H&E, 10x.

Immunohistochemistry

The tumoral cells are positive for: CD3 (Figure 6A and 6B), Perforin (Figure 7A and 7B), CD56 (Figure 8), EBER (Figure 9), CD2, CD4, CD7, CD45 (Figure 11), BCL2, CD43, and MYC. The tumoral cells are negative for: CD5 (Figure 12A and 12B), CD8, CD30 (Figure 13), CD20 (Figure 14), BCL6, CD10, MUM1, CD21, CD23, cyclinD1, ISH Kappa, and ISH Lambda. Ki67 proliferative index is evaluated at 95-100% (Figure 10A and 10B).

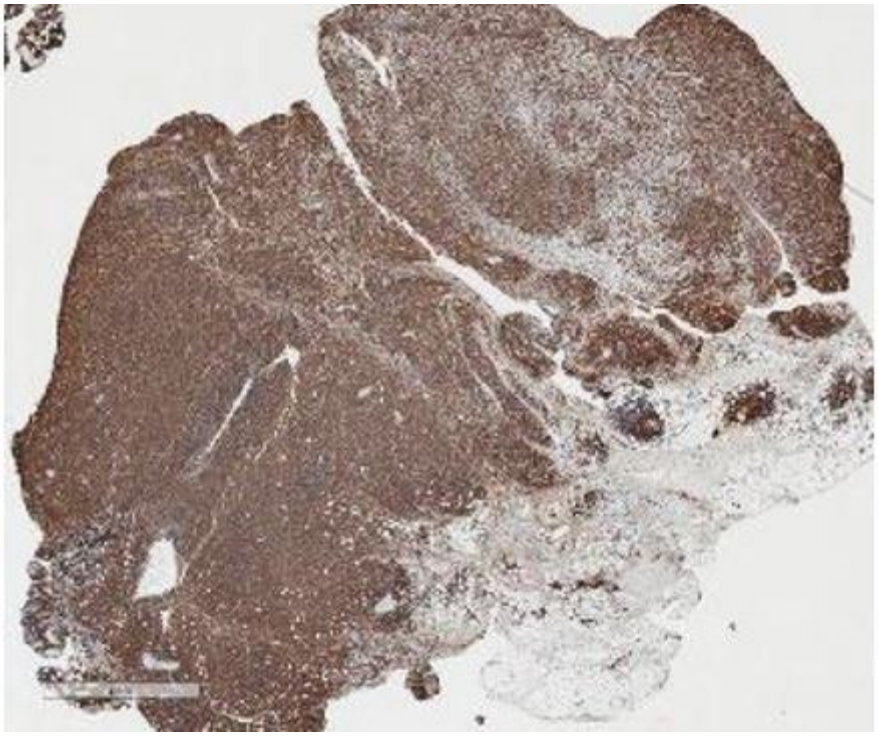

A

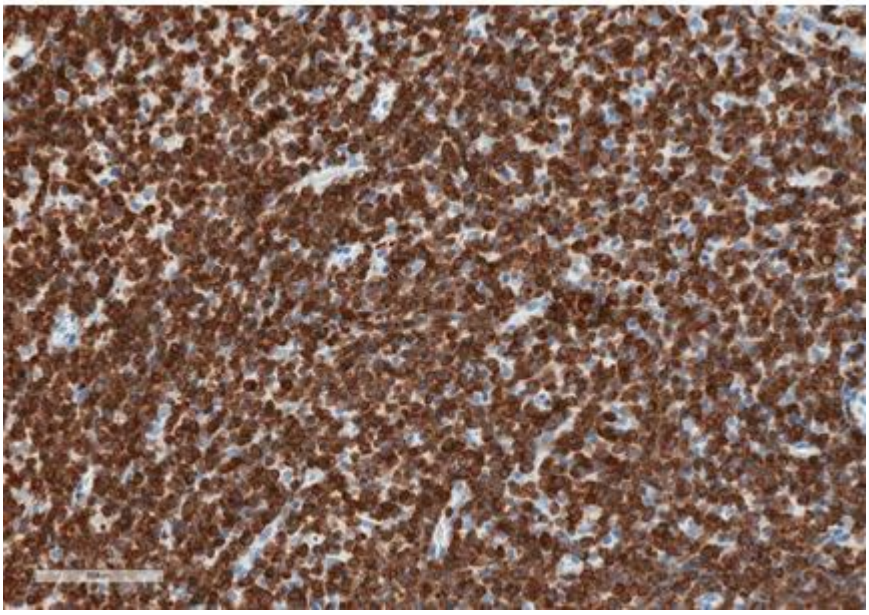

B

Figure 6: Tumoral cells stain densely for CD3; note the cytoplasmic staining. A:10x. B:200x.

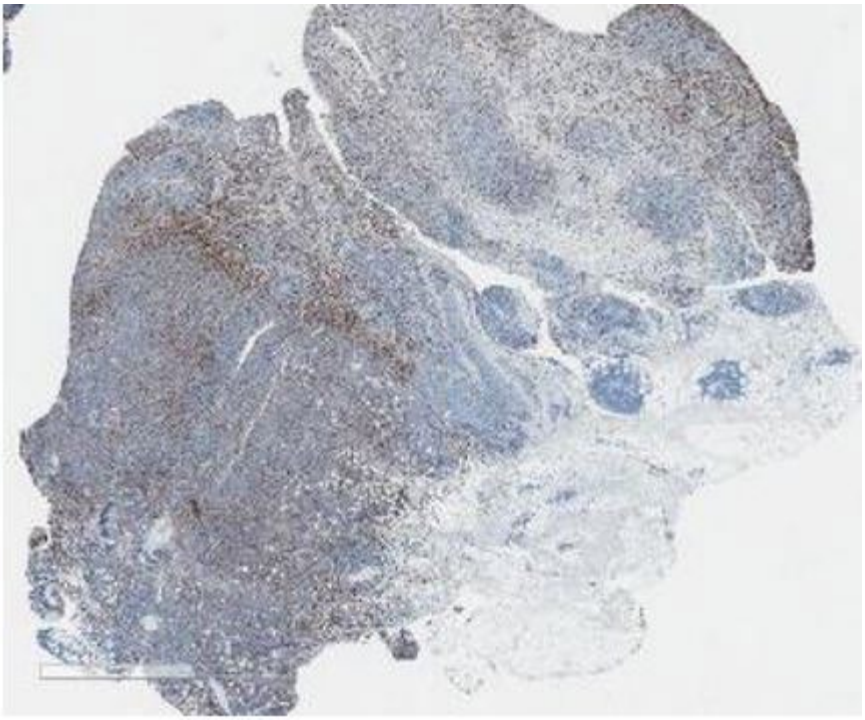

A

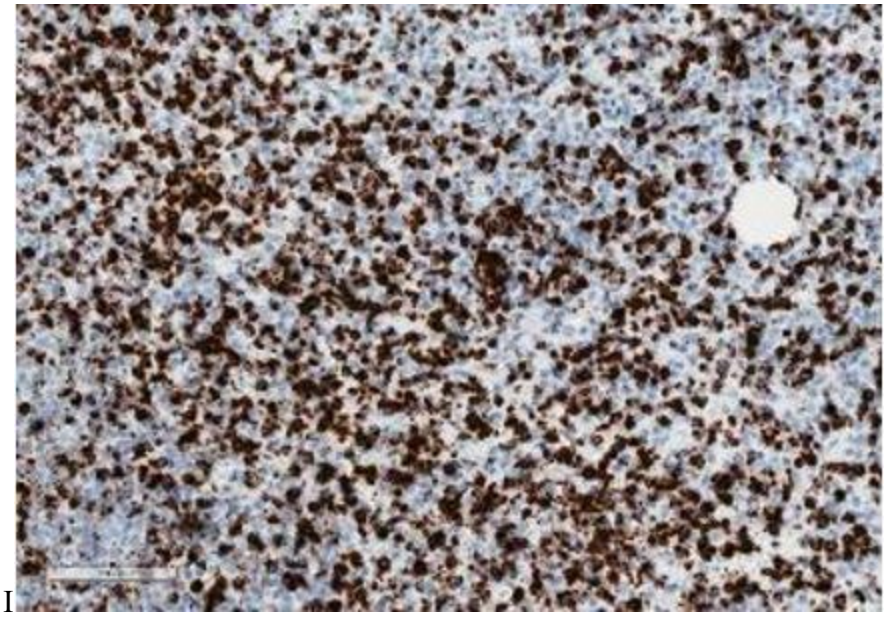

B

Figures 7: Tumoral cells are positive for Perforin. A: 10x B: 200x.

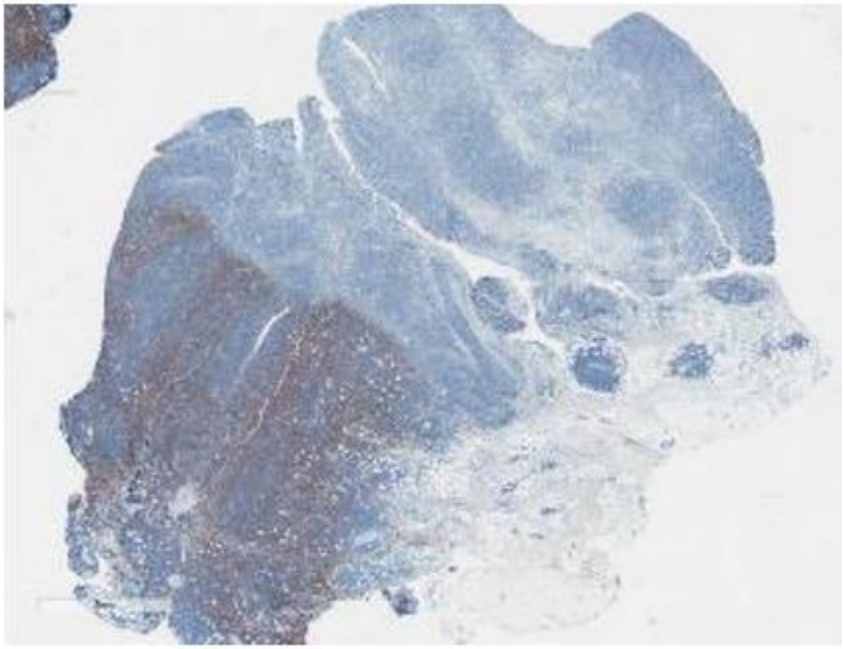

Figure 8: Tumoral cells are positive for CD56. 10x.

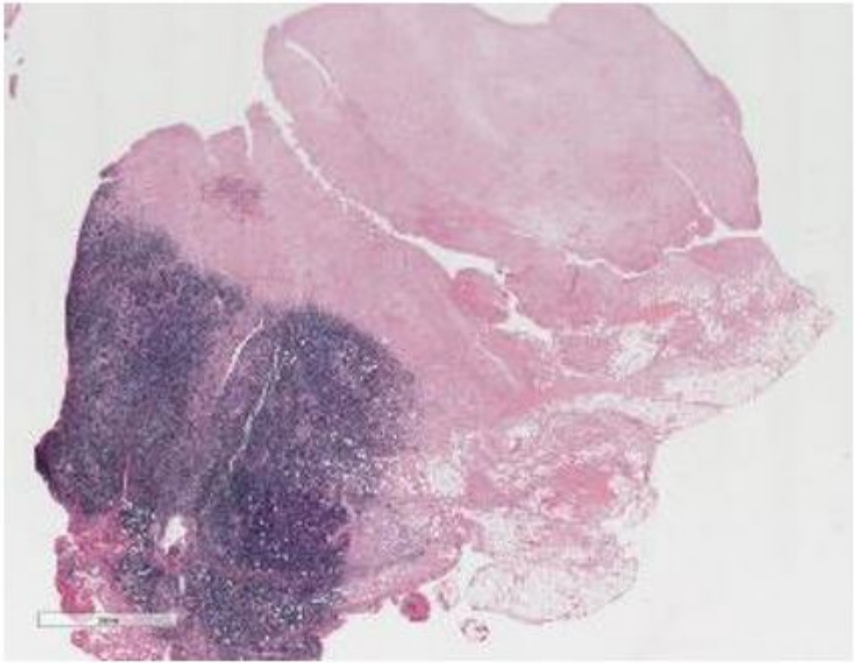

Figure 9: Tumoral cells are positive for EBER. 10x.

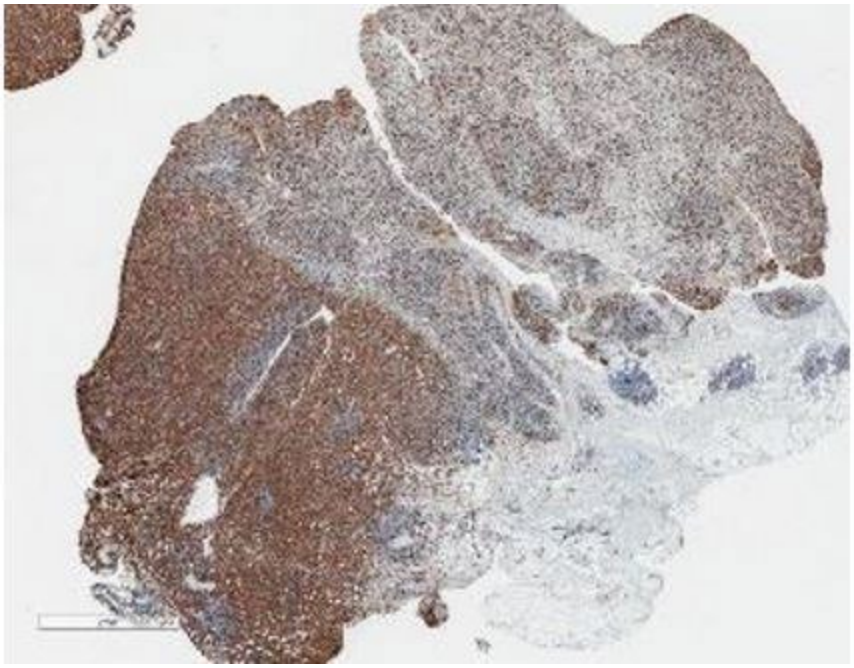

A



B

Figure 10: Proliferation index Ki67 is evaluated at 90-95%. A: 10x. B: 200x.

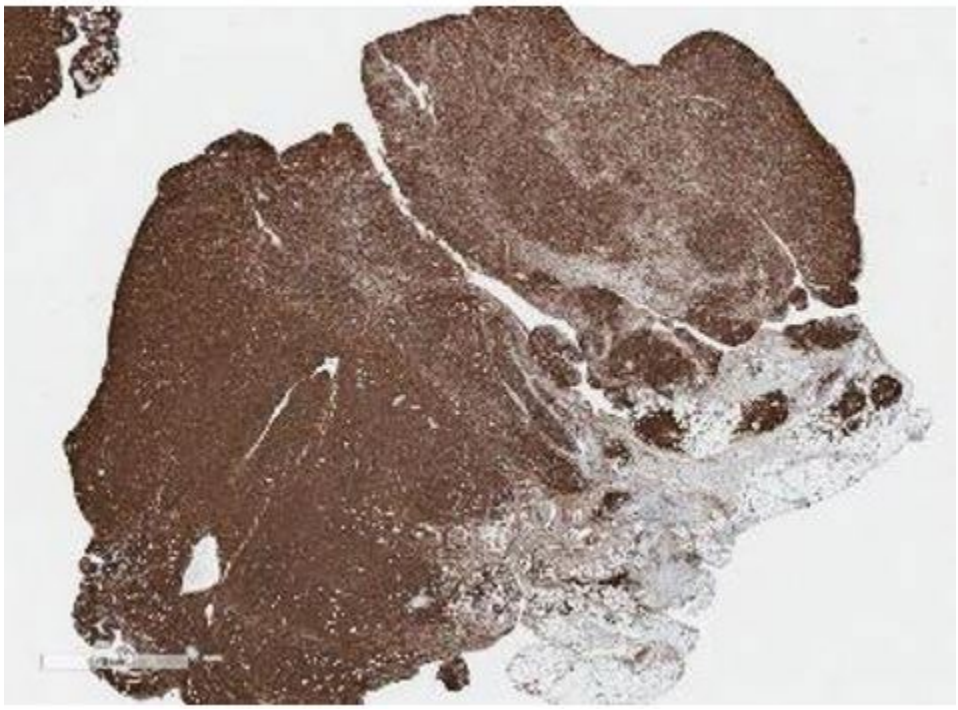

Figure 11: Tumoral cells stain densely for CD45. 10x.

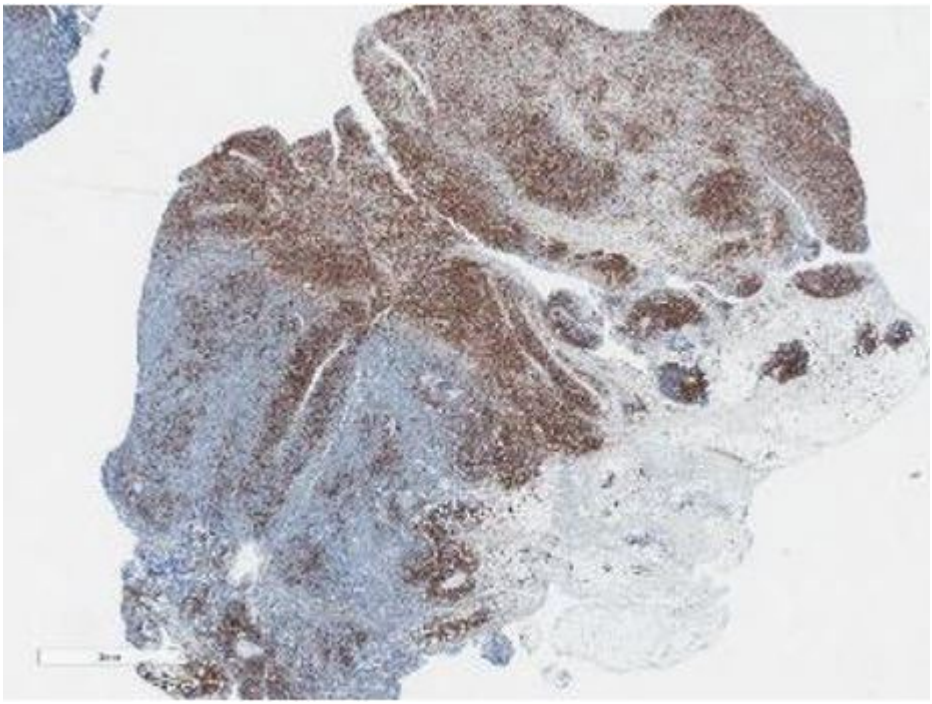

A

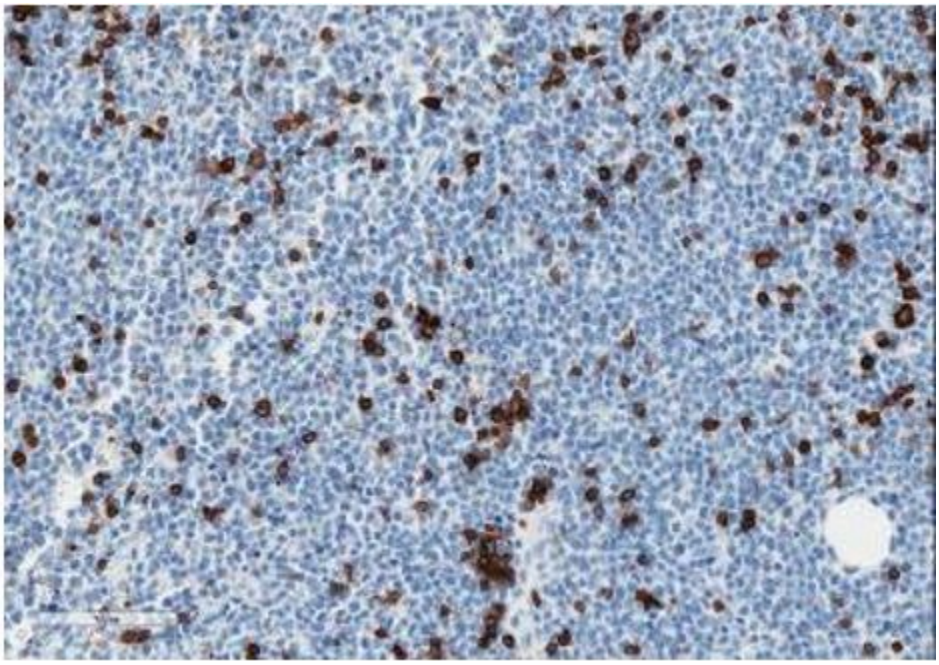

B

Figures 12: Tumoral cells are negative for CD5, consistent with a loss of expression. Positive internal control are reactive T cells. A: 10x. B: 200x.

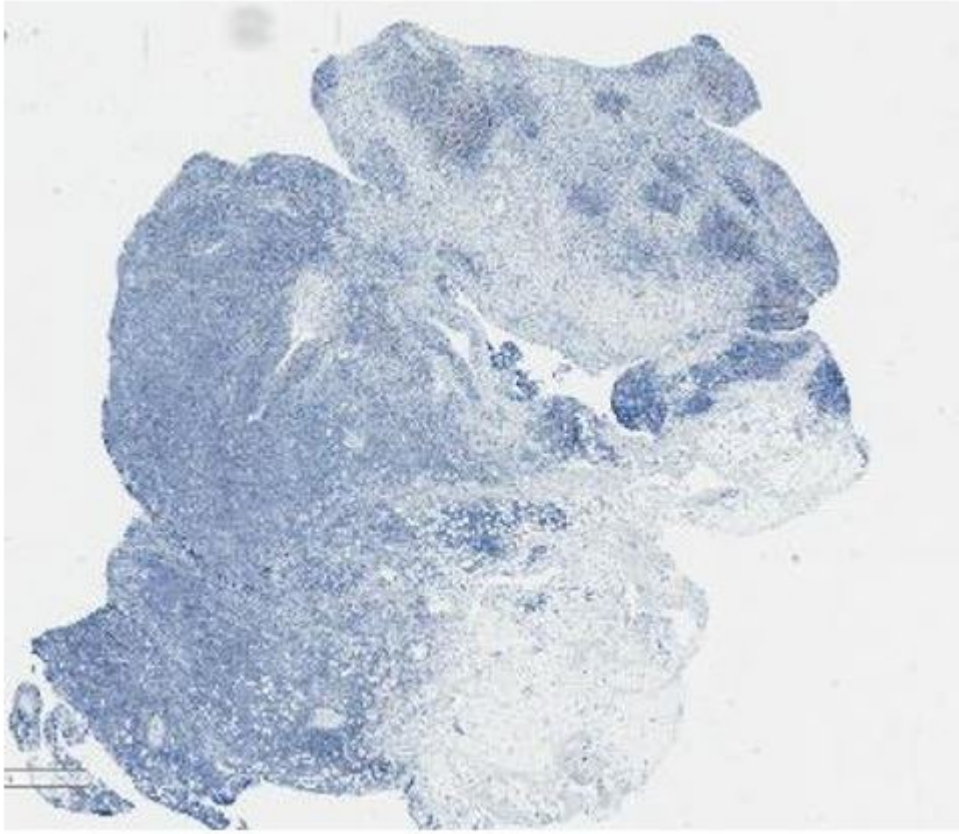

A

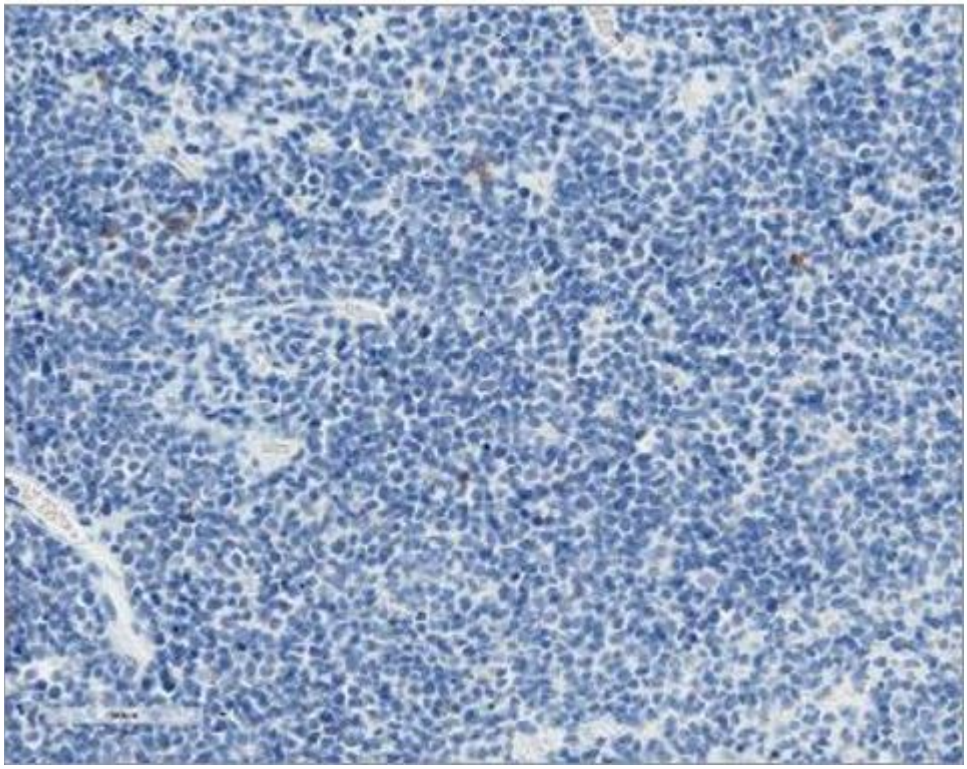

B

Figures 13: Tumoral cells are negative for CD30. A: 10x. B: 200x.

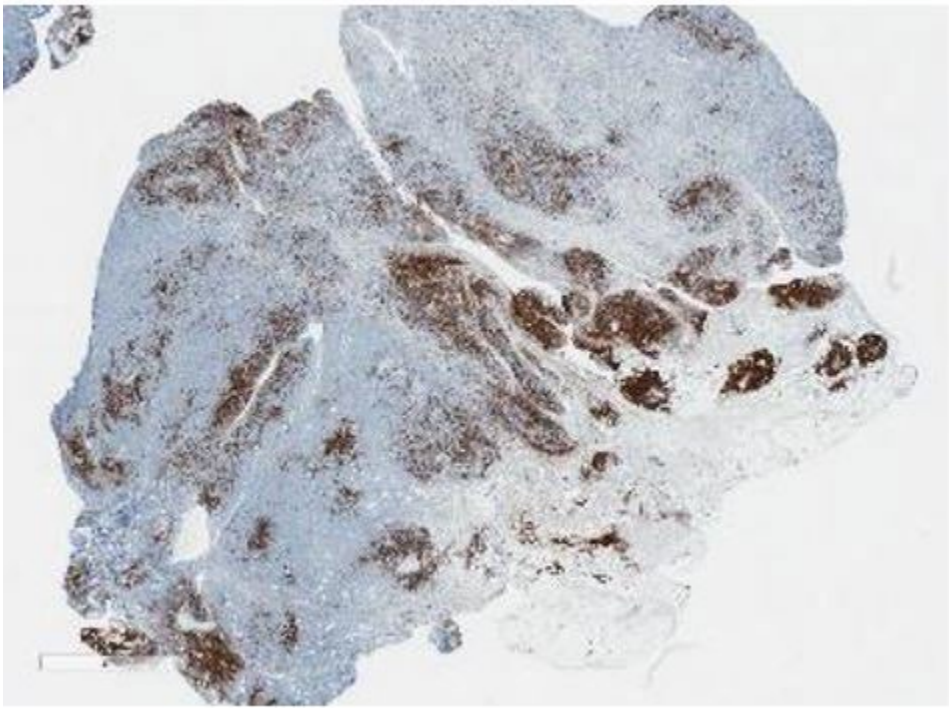

Figure 14: Tumoral cells are negative for CD20. Positive internal control are reactive B cells. 10x.

Discussion

When approaching the differential diagnoses of mature T/NK cell lymphoma, one should always rule out more common lymphoid lesions using pan lineage markers[1]. Mature B cell lymphomas can be ruled out with CD20/CD79a; myeloid neoplasms can be ruled out with MPO/c-kit/lysozymes; dendritic neoplasms can be ruled out with CD68/CD163; and precursor (immature) lymphomas can be ruled out with TdT/CD34/CD99[2].

T/NK cell lymphomas usually will stain with one or more of the pan-T cell markers (CD2, CD3, CD5, CD7, CD4/CD8), but loss-of-expression of these markers is common. As such, pan-T cell markers should be ordered as a panel[2].

Soo et al. proposed an algorithm immunohistochemical approach to mature T/NK cell lymphomas (Figure 16)[1]. When T cell lineage is confirmed with pan-T cell markers, first rely on CD30. If CD30 is positive, use ALK to subtype. If CD30 is negative, look at the cytotoxic granules (CG) status. If CG is positive, use CD56 and EBER to subtype. If CG is negative, use CD4 and CD8 to subtype. Using this algorithm, our case can easily be immunohistochemically classified as an Extranodal NK/T cell lymphoma, nasal type (ENKTL).

ENKTL is categorized as a mature T/NK cell neoplasm and is a prevalent disease in Asia and Central/South America[2]. Patients are typically 44 to 54 years-old and the most common location is the nose, although it has been reported at other sites (skin, soft tissue, gastrointestinal tract, testes)[2].

ENKTL is initially found as progressive ulceration and "necrotic granuloma" in the nasal cavity, palate, and nasopharynx[3]. The tumor frequently invades adjacent tissues such as facial skin, paranasal sinus, and orbits. The most common symptoms at the time of diagnosis are nasal obstruction and/or epistaxis[3]. The swelling of cheek or orbit, sore throat, and hoarseness are also major symptoms of ENKTL[3]. In addition, systemic symptoms such as prolonged fever and weight loss are commonly seen. ENKTL is strongly associated with EBV infection, which suggests a pathogenic role of the virus[2].

In retrospect, our case is clinically classical given the patient's age and location of tumor close to the nasopharynx.

On histology, ENKTL is heterogenous, ranging from a monomorphic cell population with medium-sized nuclei to a polymorphic cell population with small-to-large-sized nuclei[2]. ENKTL typically shows prominent reactive inflammation, extensive ulceration and angioinvasion which can lead to areas of ischemic necrosis[2]. Our case does display some classical histologic features of ENKTL, including monomorphic proliferation of medium-sized lymphocytes and prominent reactive inflammation. In addition, the prominent apoptotic debris seen in our case can be a histologic clue to EBV infection[2].

The typical immunohistochemical profile of ENKTL fits our case. Defining features are positivity for CG and EBER, and loss of CD5 expression[2]. In addition, ENKTL is usually positive for CD2, CD3, CD56, and CD43; variable for CD7; and usually negative for CD30,

CD4 and CD8[2]. Of note, cases that are CD3- and CD56- are still classified as ENKTL if CG and EBER are positive; and CD30 is reported to be positive in up to 30% of cases[2].

ENKTL is a heterogenous group from a molecular perspective, but most cases do not show T cell receptors (TCR) gene rearrangements[2]. Molecular studies in our case showed no TCR gene rearrangements on both frozen tissue specimen and paraffin embedded tissue blocks.

ENKTL, which was initially termed "lethal midline granuloma", classically carries a poor prognosis given its resistance to chemotherapy, but recent studies show a variable prognosis with the advent of upfront radiotherapy[2]. Early diagnosis of ENKTL is essential to treat patients promptly but even in early clinical stages, five-year survival rates had been around 50%[3]. Immune checkpoint inhibitors could be a favorable treatment in chemotherapy-resistant ENKTL patients, and several clinical trials with PD-1/PD-L1 blockade are ongoing[3]. Our patient received chemotherapy, followed by radiotherapy. PD-L1 immunohistochemistry was performed in the advent of disease progression and shows >50% of tumoral cells staining positive when compared to EBER.

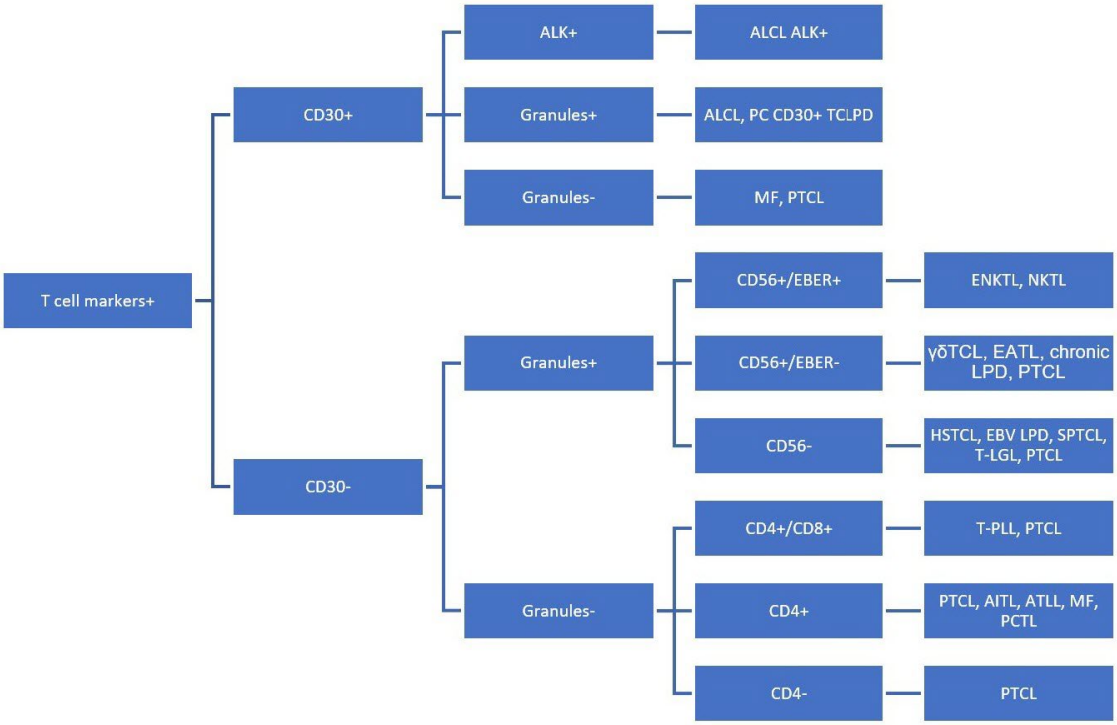

Figure 15: Immunohistochemical approach to T/NK cell lymphomas. Modified from: Soo, K. L., et al. "An algorithmic approach to the diagnosis of NK and T cell lymphomas." *Pathology* 43.7 (2011): 673-681.

Final Diagnosis: Extranodal NK/T cell lymphoma, nasal type.

References

1. Soo KL et al. An algorithmic approach to the diagnosis of NK and T cell lymphomas. Pathology; 43.7 (2011): 673-681

2. Swerdlow SH et al. WHO classification of tumours of haematopoietic and lymphoid tissues; Fourth edition; Lyon: WHO (2017).

3. Harabuchi Y et al. Extranodal Natural Killer/T-Cell Lymphoma, Nasal Type: Basic Science and Clinical Progress. Front Pediatr. 2019;7:141.