neuro
Institut-Hôpital neurologique de Montréal
Montreal Neurological Institute-Hospital

November 18, 2019 | #OpenScienceinAction | www.theneuro.ca

Atlas of Normal Intracerebral EEG

Jean Gotman, PhD
Montreal Neurological Institute

Open Science Symposium

McGill
Centre universitaire de santé McGill
McGill University Health Centre

Key Collaborators

Birgit Frauscher, MD
Neurologist

Nicolas von Ellenrieder, PhD
Research Associate

François Dubeau, MD
Neurologist

Natalja Zazubovits, MSc
Research Assistant

How do we interpret a standard EEG?

- A large proportion of medical tests consist in comparing a measure made in one individual to that made in a large number of healthy individuals to assess if the measure is outside the range of normality.
- This is the case for standard EEGs (electroencephalograms) recorded by sticking electrodes on the scalp.
- We know what the EEG of healthy individuals looks like at all ages, in different conditions (during wakefulness and various sleep stages) because the EEG of such healthy volunteers are easily obtained.
- The EEG of a patient is interpreted by comparing it, qualitatively or quantitatively, to that of healthy individuals

What is intracerebral EEG?

- In patients with medically refractory epilepsy, surgical resection of the part of the brain generating seizures may provide a cure.
- The pre-surgical evaluation consists in several tests that attempt to localize the epileptogenic region: EEG, MRI, PET, neuropsychological evaluation. The EEG is particularly important because it can be recorded during seizures.
- These tests are non-invasive or minimally invasive
- In some patients these tests do not provide a clear answer regarding the localization of the epileptogenic zone
- It is possible to insert electrodes in the brain to overcome the fundamental weaknesses of scalp EEG, its relatively poor spatial resolution and particularly its inability to see deep in the brain.
- This is an invasive but relatively safe procedure.

Why an atlas of the normal intracerebral EEG?

- Intracerebral EEGs have been recorded for decades, relying almost exclusively on trying to localize the origin of epileptic seizures.
- The background EEG (outside of seizures) also carries a lot of information about the condition of the brain but it is almost impossible to interpret because we do not know what the intracerebral EEG of the healthy brain looks like in different anatomical regions and in different conditions (wake, sleep)

How to obtain an atlas of the normal intracerebral EEG?

- Ask for healthy volunteers to have electrodes inserted in their brain….
- Select in each patient with intracerebral electrodes the few electrode contacts that are *very likely* to be in a healthy part of the brain.
- Collect data from a large number of patients in the hope that putting together all their “normal” contacts will give us a complete picture of the intracerebral EEG in the different parts of a healthy brain

Intracerebral electrodes in a single patient

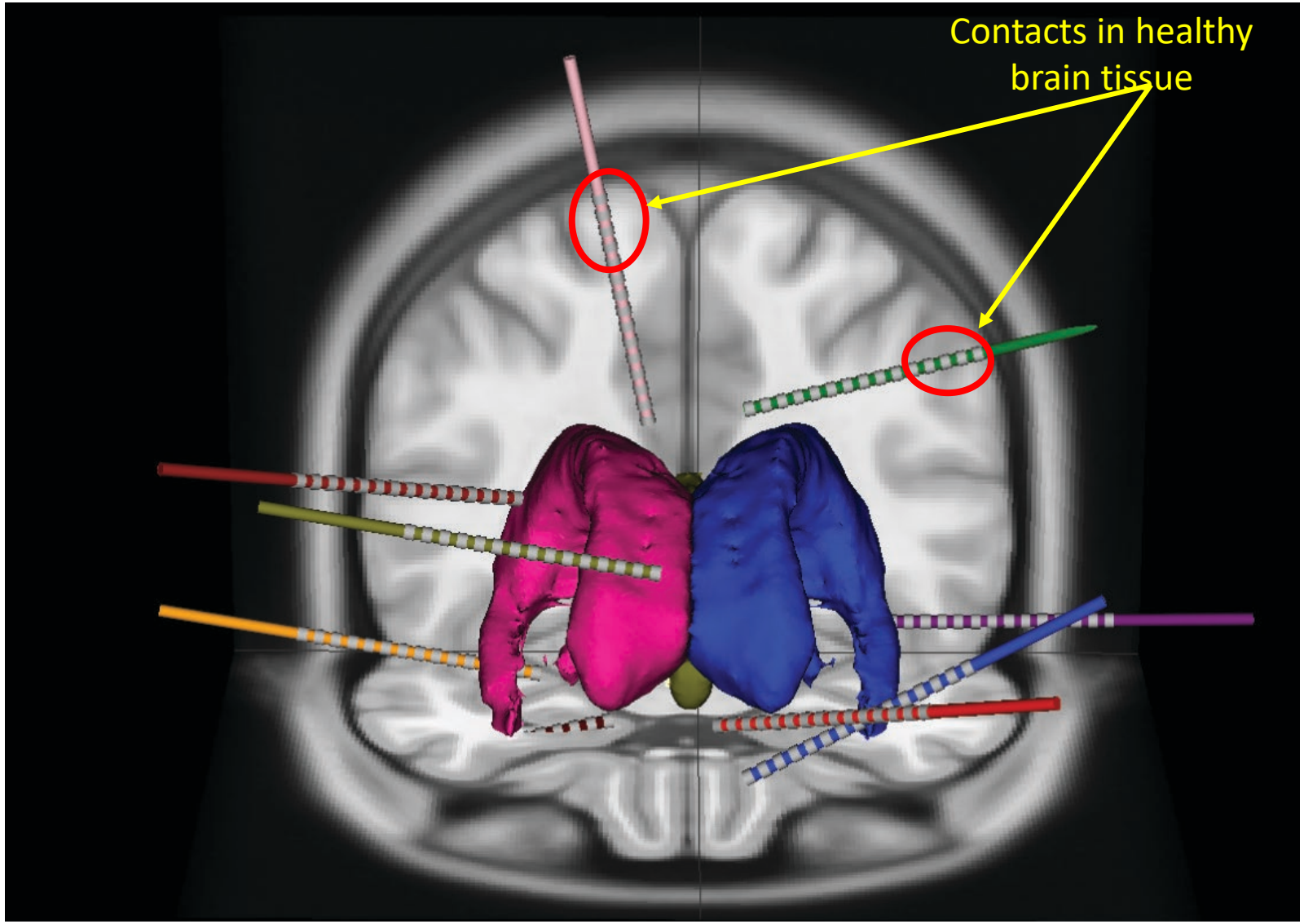

Selection of normal channels

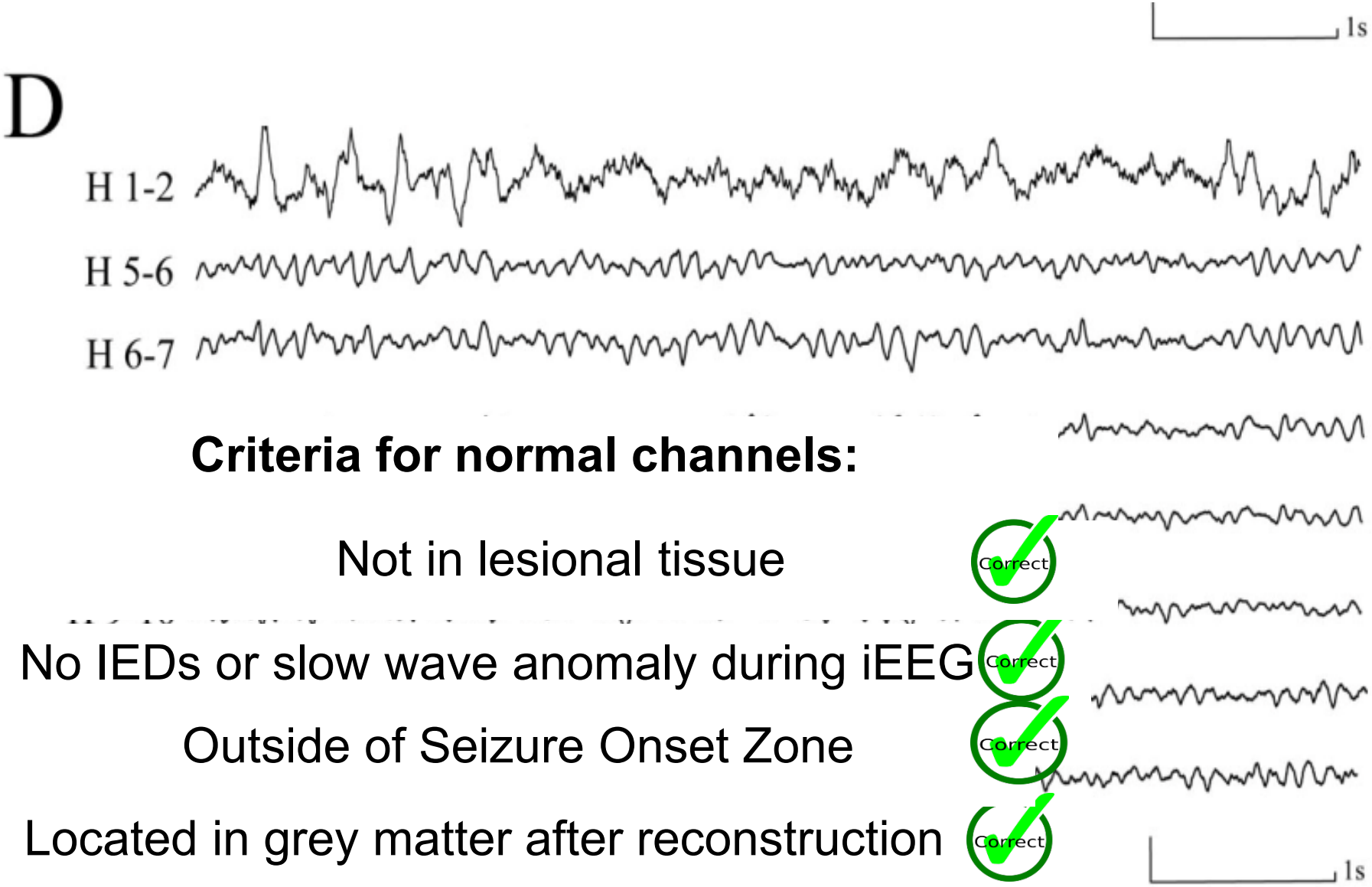

Criteria for normal channels:

Not in lesional tissue

No IEDs or slow wave anomaly during iEEG

Outside of Seizure Onset Zone

Located in grey matter after reconstruction

MNI Multicenter i-EEG Atlas

1785 healthy channels from 106 patients

2.7 channels per cm^3 of cortical grey matter volume

1520 S-EEG channels, 265 grid / strip channels

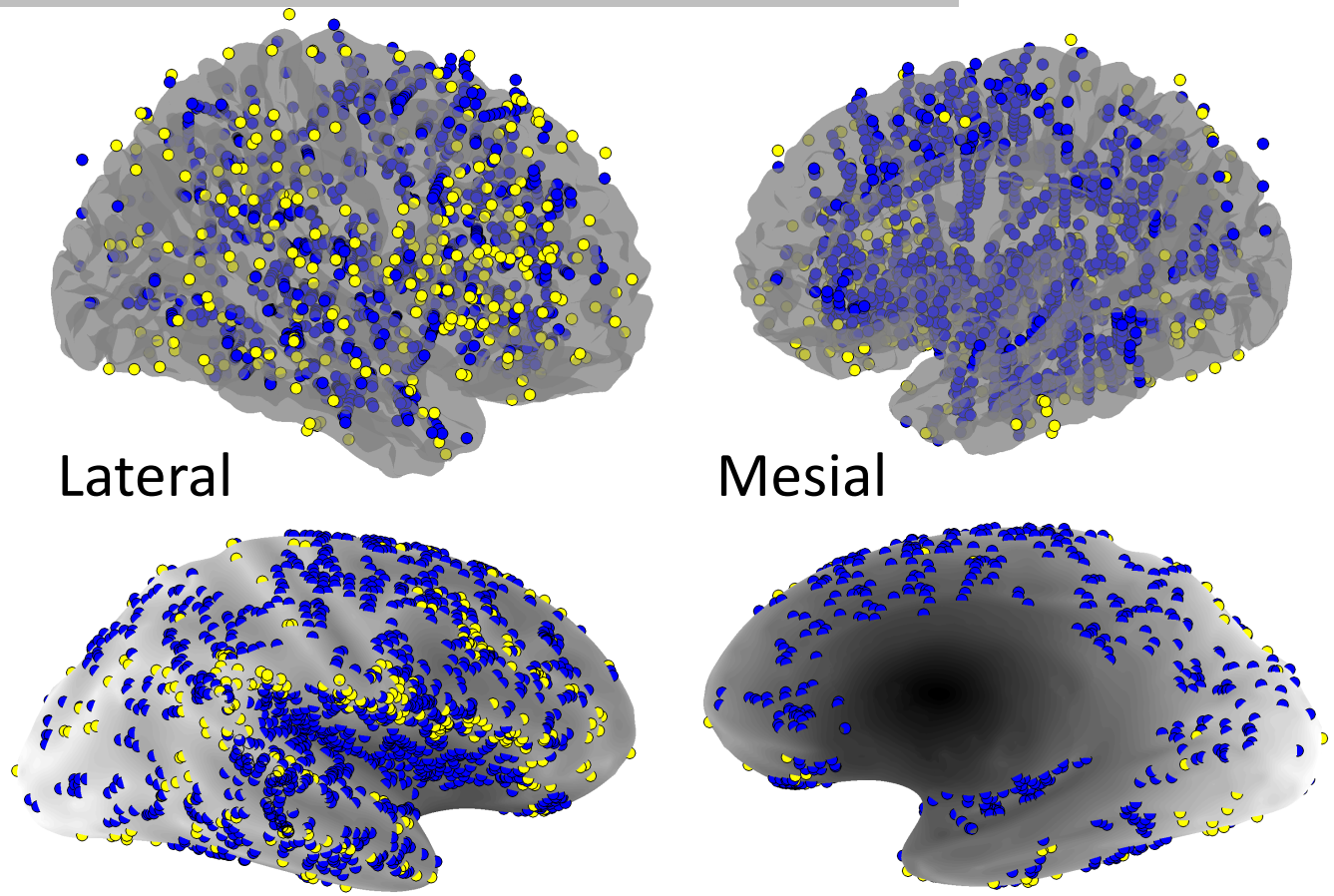

MNI Multicenter i-EEG Atlas

doi:10.1093/brain/awy035 BRAIN 2018: 141; 1130–1144 | 1130

BRAIN
A JOURNAL OF NEUROLOGY

Atlas of the normal intracranial electroencephalogram: neurophysiological awake activity in different cortical areas

Birgit Frauscher,[1,2] Nicolas von Ellenrieder,[1] Rina Zelmann,[1,3] Irena Doležalová,[4] Lorella Minotti,[5] André Olivier,[1] Jeffery Hall,[1] Dominique Hoffmann,[5] Dang Khoa Nguyen,[6] Philippe Kahane,[5] François Dubeau[1] and Jean Gotman[1]

MNI-McGill, Université de Montréal, Université Grenoble-Alpes

MNI multicenter i-EEG Atlas

Posterior to anterior gradient of increasing frequencies

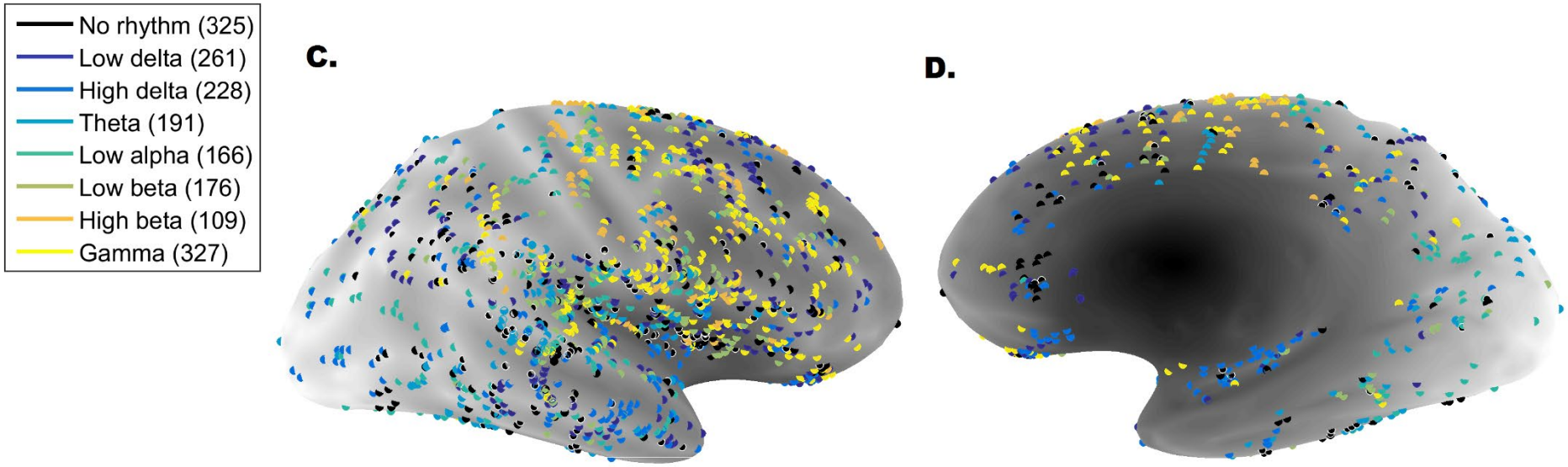

Frauscher B et al. Brain 2018

Power spectra of the different lobes

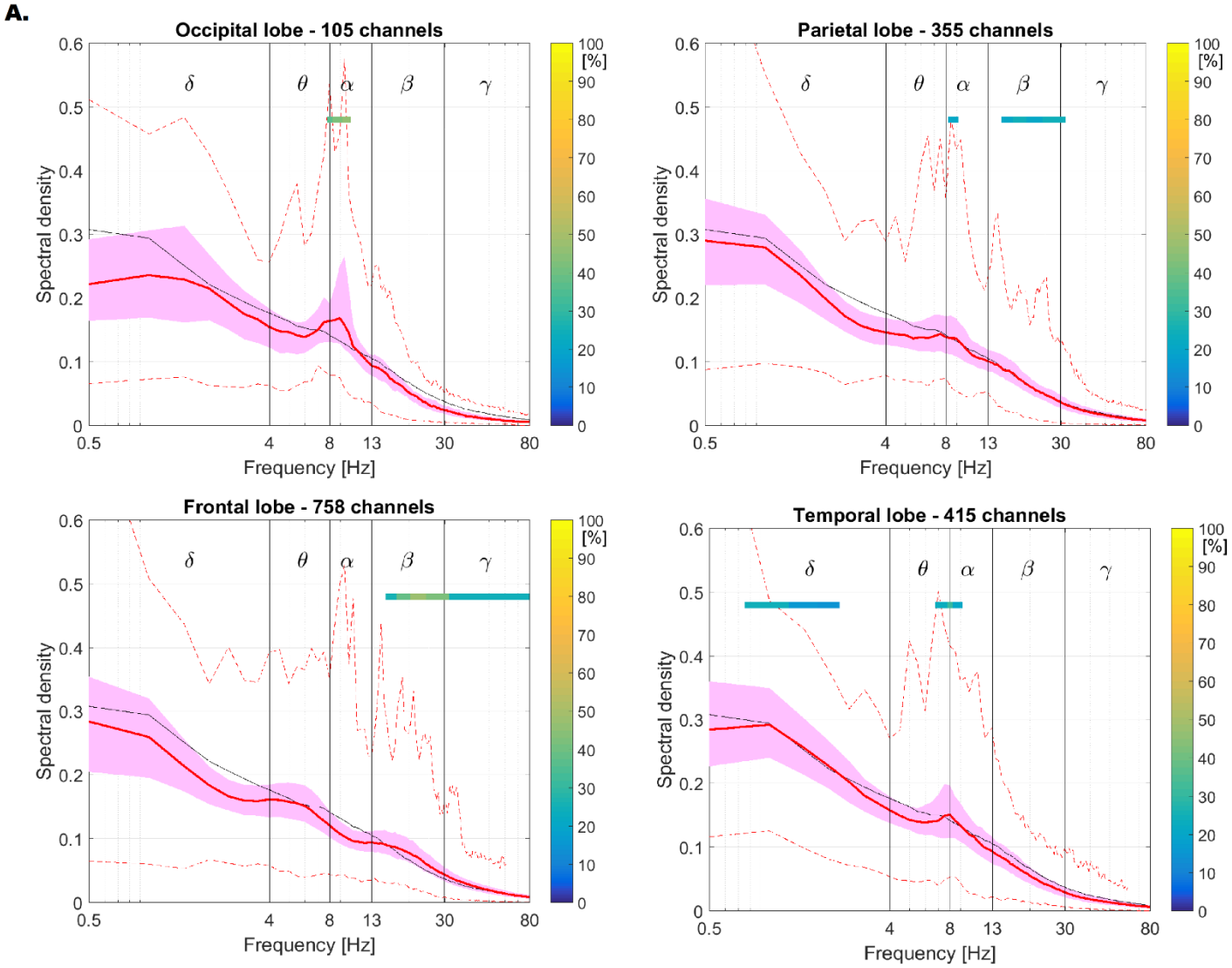

Frauscher B et al. Brain 2018

Alpha peak in extra-occipital regions

Alpha activity is not only present in the occipital lobe, but also the parieto-temporal region, but at lower frequencies

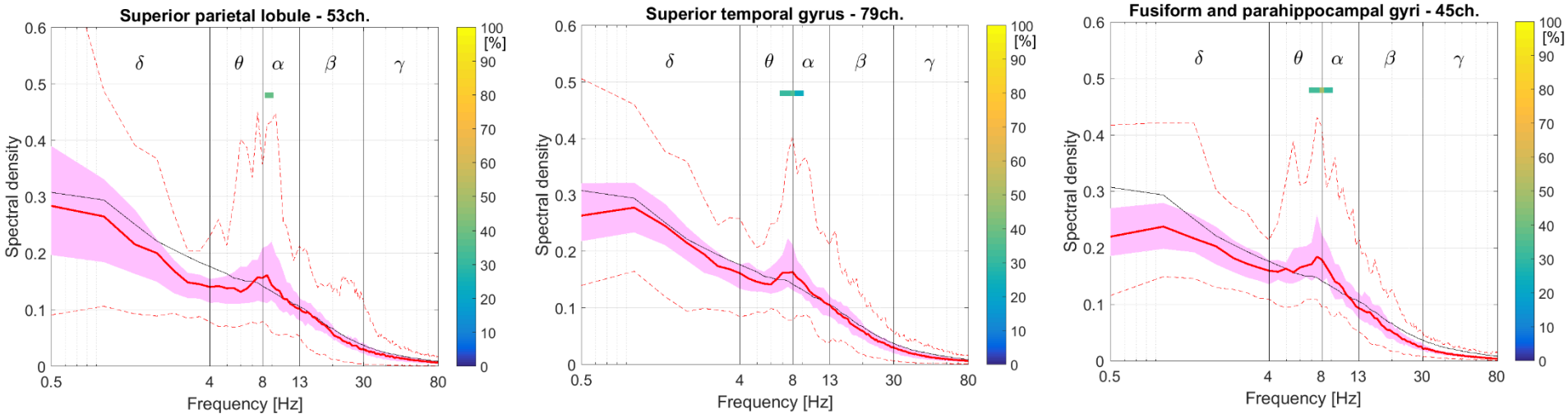

Frauscher B et al. Brain 2018

Regions with delta peaks during wake

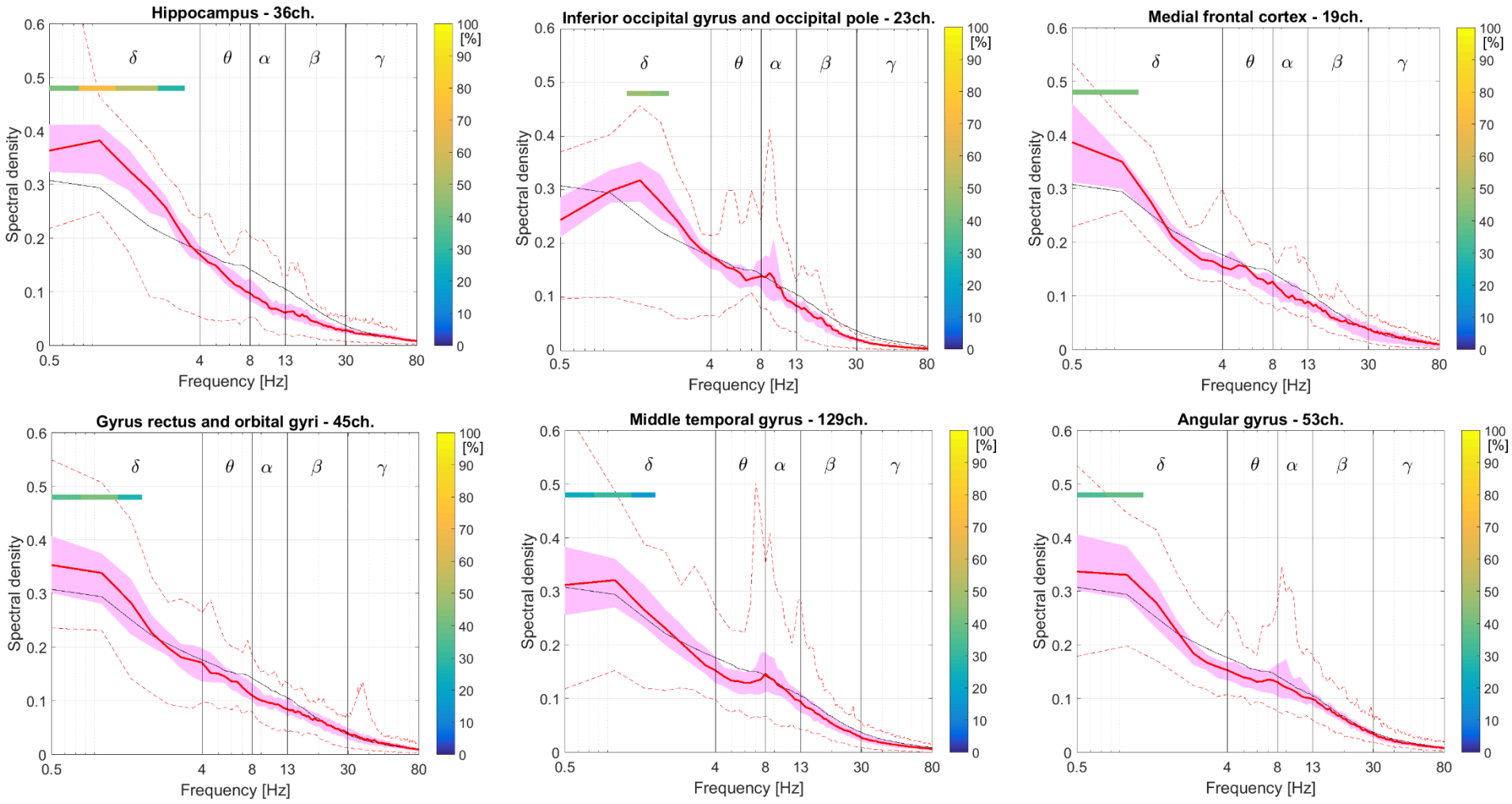

Frauscher B et al. Brain 2018

High Frequency Oscillations

- High Frequency Oscillations, between 80 and 500 Hz, have recently been found to be a potentially important biomarker of the epileptogenic zone
- One difficulty in their use is that there are also normal High Frequency Oscillations related to cognitive processes and it is very difficult to separate these physiological oscillations from the pathological oscillations of epileptic tissue.

RESEARCH ARTICLE

High-Frequency Oscillations in the Normal Human Brain

Birgit Frauscher, MD,[1,2] Nicolás von Ellenrieder, PhD,[1] Rina Zelmann, PhD,[1,3]
Christine Rogers, BA,[4] Dang Khoa Nguyen, MD, PhD,[5] Philippe Kahane, MD, PhD,[6]
François Dubeau, MD,[1] and Jean Gotman, PhD[1]

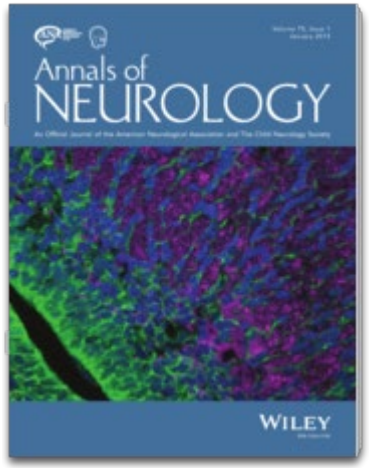

High-frequency oscillations (80 - 250 Hz)

- Mean ripple rate: 2.5 /min (95th percentile 9.6 /min)

95th percentiles

Individual rates

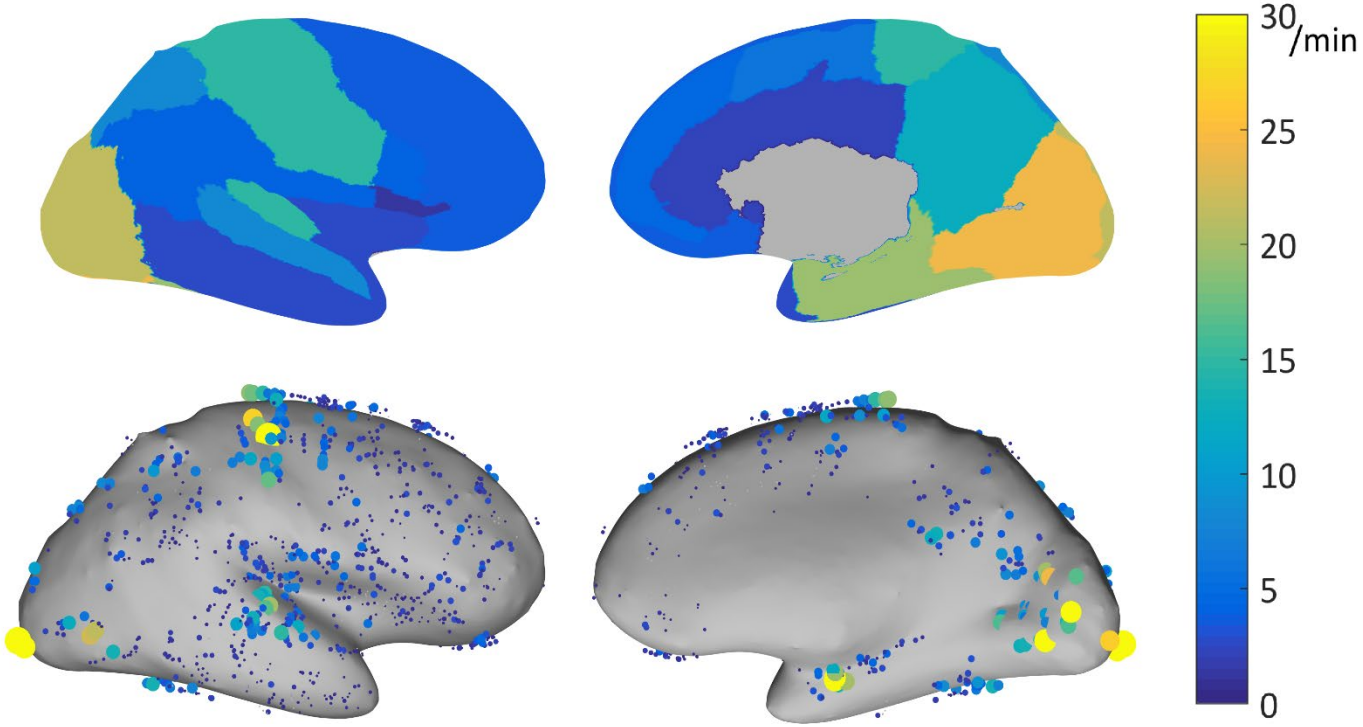

Frauscher B et al. Ann Neurol 2018

High-frequency oscillations (>250 Hz)

- 74 % of channels had no fast ripples, whereas only 5 % of channels had a rate of at least one fast ripple every 5 minutes.

- 80 % of fast ripples had a frequency below 330 Hz

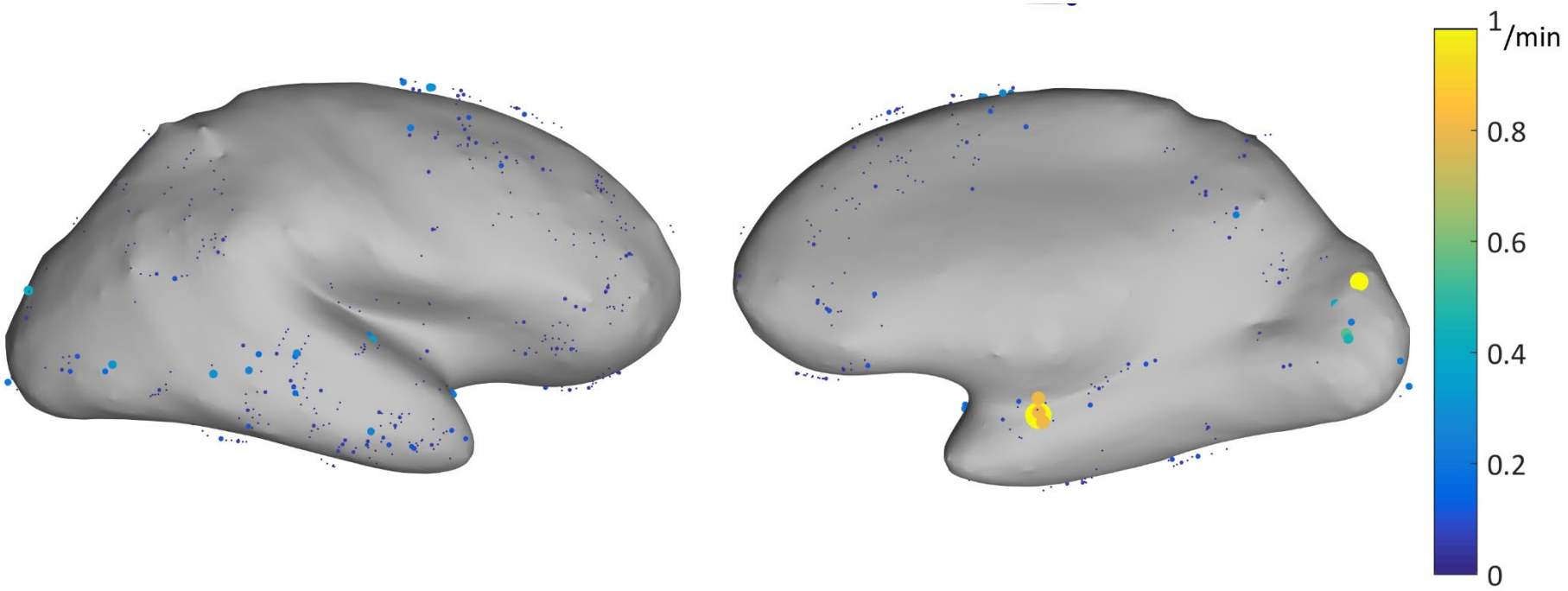

Frauscher B et al. Ann Neurol 2018

How the human brain sleeps: Direct cortical recordings of normal brain activity

Nicolás von Ellenrieder, PhD[1]; Jean Gotman, PhD[1]; Rina Zelmann, PhD[1,2]; Christine Rogers, BSc[1], Dang Khoa Nguyen, MD PhD[3]; Philippe Kahane, MD, PhD[4]; François Dubeau, MD[1]; Birgit Frauscher, MD[1,5]

Submitted

Distribution & Frequency of Spindles

- Highest rates of are found in the fronto-parietal neocortex
- Rostro-caudal decrease in spindle frequencies

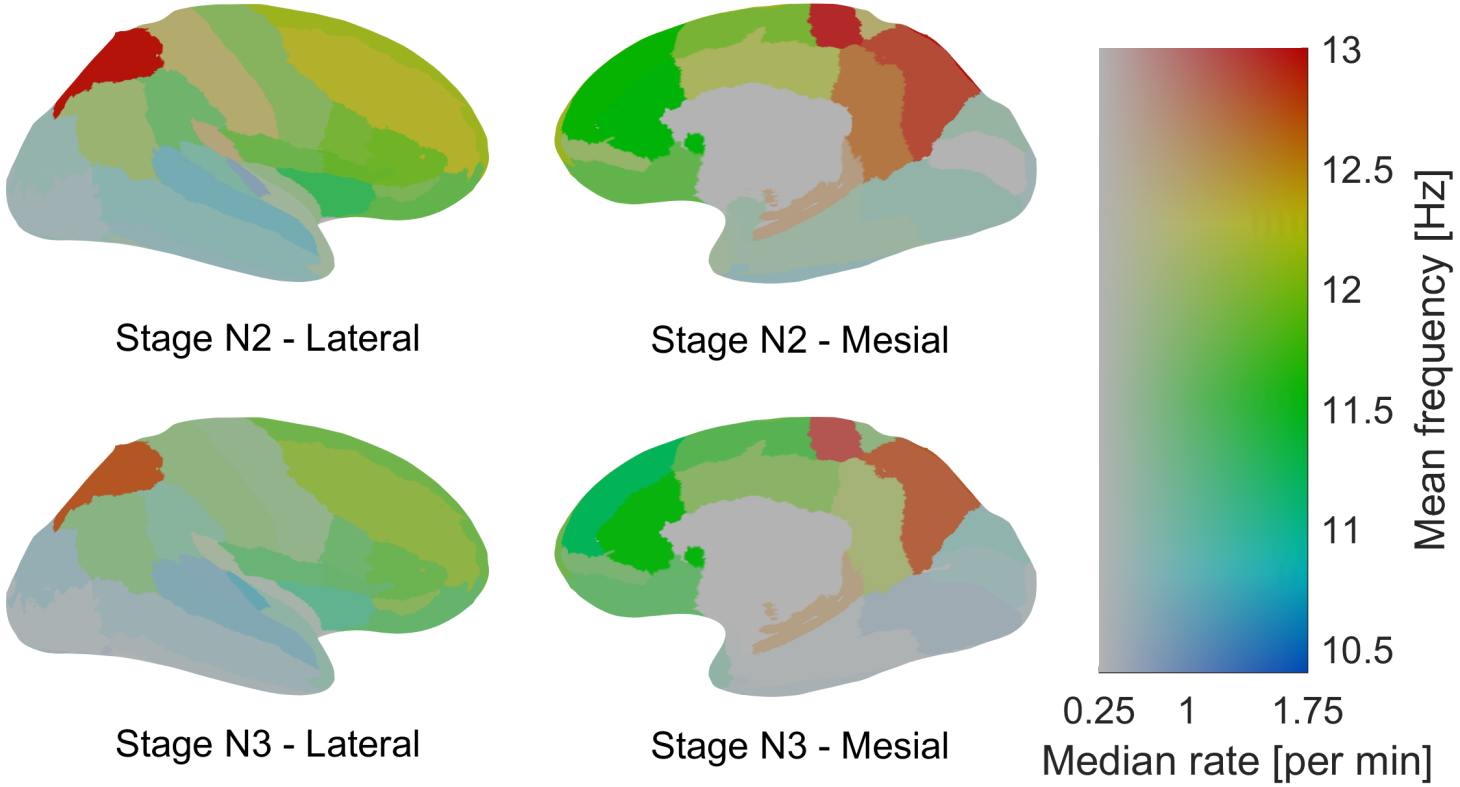

Von Ellenrieder et al. Submitted

Distribution of Sleep Slow Waves

- As expected, significant increase in slow waves during N3 vs. N2

- Lower rates in the calcarine cortex, precentral gyrus, transverse temporal temporal gyrus, lingual gyrus, occipital fusiform gyrus, and hippocampus

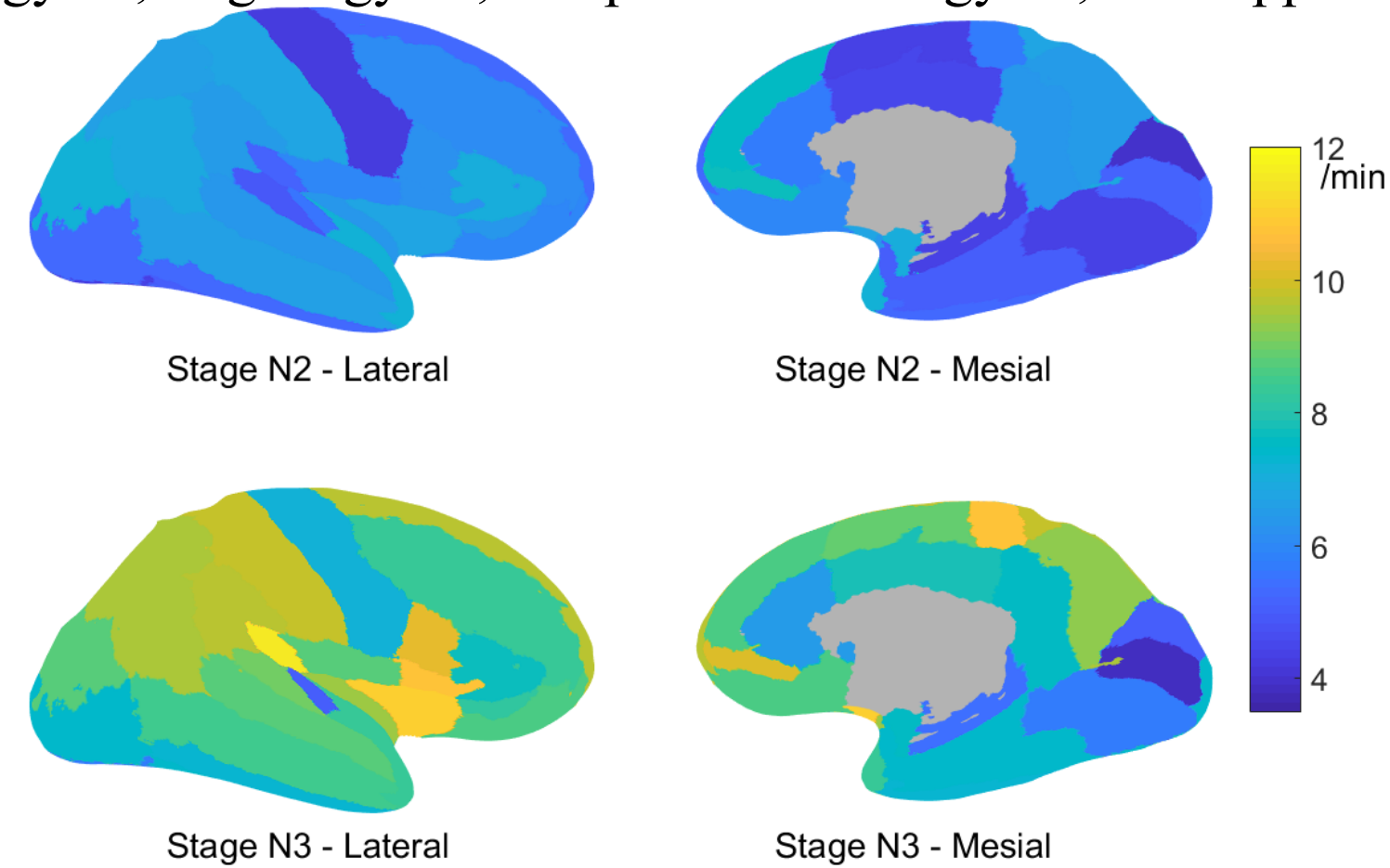

Von Ellenrieder et al. Submitted

https://mni-open-ieegatlas.research.mcgill.ca

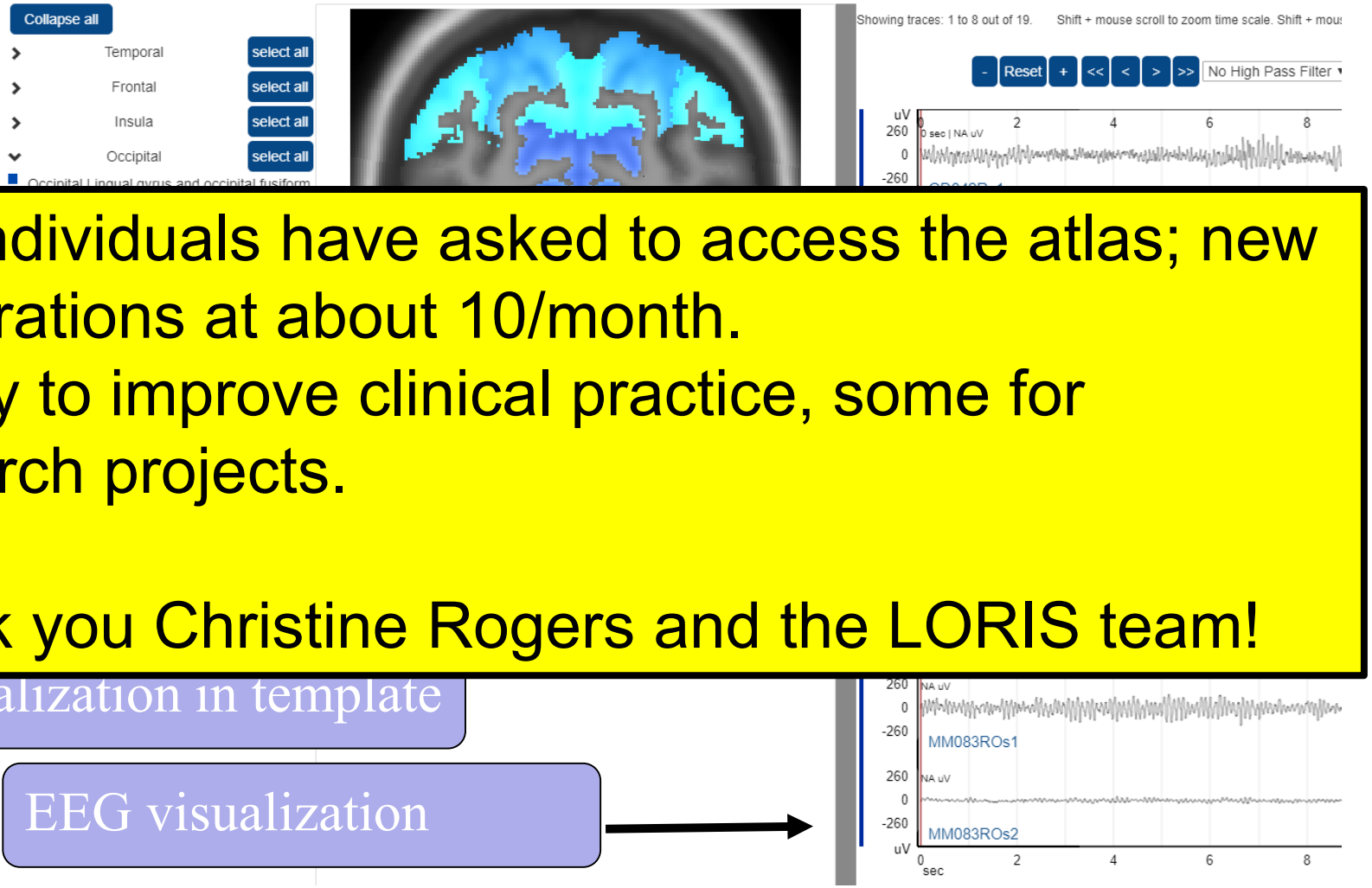

380 individuals have asked to access the atlas; new registrations at about 10/month.
Mostly to improve clinical practice, some for research projects.

Thank you Christine Rogers and the LORIS team!

Visualization in template

EEG visualization

Funding

- Canadian Institutes of Health Research
- Savoy Foundation for Epilepsy

Plans for expantion of the atlas

- Plan for expansion to children: effort under way in the UK but funding could not be obtained so far
- Plan for expansion of the adult atlas by collaboration between 5 centers (MNI, CHUM, Mayo Clinic, Université Grenoble Alpes, University of Brno) to obtain better spatial coverage of some brain regions and a larger number of samples for each region: funding could not be obtained so far.

Conclusions

- **First atlas of the “normal” intracerebral EEG**
  - Not from healthy brains but as close as we can ever come
  - Atlas 1: Standard EEG frequencies during wakefulness
  - Atlas 2: High Frequency Oscillations
  - Atlas 3: Different stages of sleep
- **Open access platform**
- **Difficulty with funding an expansion of the atlas**

THE END