



Maude Abbott Medical Museum NEWSLETTER

Musée médical Maude-Abbott

Volume 3 No 1, Fall 2018

Message from the Director

The newly renovated main museum room officially opened at a gala evening ceremony on September 20. Over 100 guests attended the reception including the Dean of the McGill Faculty of Medicine, David Eidelman. Guests were able to see newly-mounted specimen displays related to the skull, systemic pathology, and anatomical models, as well as many specimens from the Maude Abbott and William Osler collections. Custom designed cabinets installed along the museum walls house artefacts related to historical aspects of the Anatomy Department, Abbott's pathology museum and the McGill Faculty of Medicine. Interactive tablets are available to illustrate and explain the artefacts and put them in a historical context. The 1822 Holmes heart and the 1826 Shepherd skeleton are on display. The famous 1940 Bell-Eastlake painting of Abbott, recently moved from the Strathcona Building lecture theater, holds a prominent "view" of the proceedings.

In this new site, we are able to display material safely and in a fashion that we believe is both interesting and educational. The project could not have been realized without the generosity of the Friends of the Maude Abbott Medical Museum, particularly those from the medical class of 1976 and Huntington ("Skip") Sheldon. We have also been fortunate to have had the assistance of the members of our Board of Directors as well as many volunteers and work study students, without whom we would not have been able to complete the project. Staff from many McGill departments helped in various ways, sometimes by finding and loaning material for exhibits and sometimes by facilitating the logistics of the project itself.

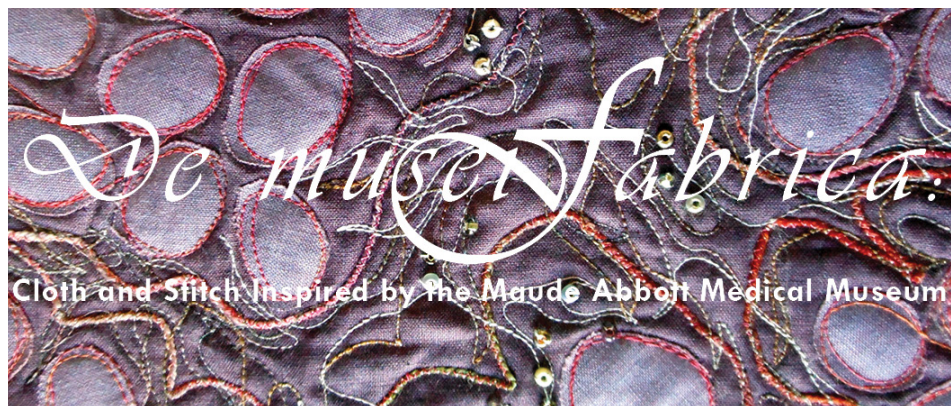
Thank you to everyone who participated in making this next step of the Museum a great success.

Rick Fraser, Director

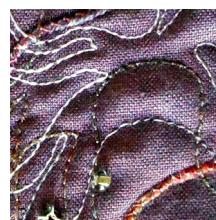
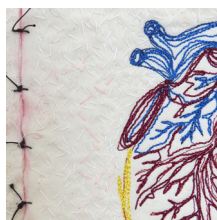
New Exhibits

An exhibit of artwork and museum artefacts was mounted at the Osler Library of the History of Medicine in May, 2018. Six Montreal textile artists, **Helena Scheffer, Lauma Kristina Cenne, Dianne Robinson, Michele Meredith, Colleen Paul, and Heather Dubreuil**, known collectively as Text'art, derived inspiration for their work from objects in the museum's collections, including such varied items as surgical instruments, wax models, pathology specimen jars and an engraving of *Digitalis purpurea*. The opening vernissage was attended by over 70 guests. The exhibit was unfortunately cut short by the McIntyre Building terrace fire on July 13; fortunately, none of the artworks or museum artefacts on display were permanently damaged.



Lt: *Embryon in Mola*
by Colleen Paul.



Thank You to the Friends of the Museum

Thanks to the gifts and donations from the Friends, a new cabinet to house the 1914 skeleton mounted à la Beauchêne has been completed.

The project we are proposing to our Friends this year is to clean and offer conservation treatment to the collection of skeletal specimens donated to the McGill museum by the Army Medical Museum in Washington, D.C. in 1907 (see the exhibit about this on the Museum's website). The bones came from soldiers of the American Civil War and need care to properly preserve them and provide them the respect they deserve.



Lt: Tibia/Fibula. The tibia consists almost entirely of a sequestrum surrounded by a thick involucrum. The US Civil War soldier sustained a gunshot fracture of the ankle at Fort Wagner on July 18, 1863. The ankle was amputated on July 25 and the patient was discharged December 4. Chronic osteomyelitis ensued and the leg was amputated below the knee on May 6, 1879. See the online exhibit "War, Bones and Books" at <https://www.mcgill.ca/medicalmuseum/exhibits/>

Rt: Skeleton, mounted à la Beauchêne, housed in new cabinet.



Opening Reception



Above: Dr. Susan Kelen and André Vito Lametti view video on interactive display.

Rt: Dr. Denis Osmond and Dean David Eidelman.

Below Lt to Rt: Dr. Jim Martin and Dr. Tom Hutchinson;
Dr. Robert Funnell, reading the small print on cardiac
pacemakers; Guests listening to Dr. Eidelman's remarks.

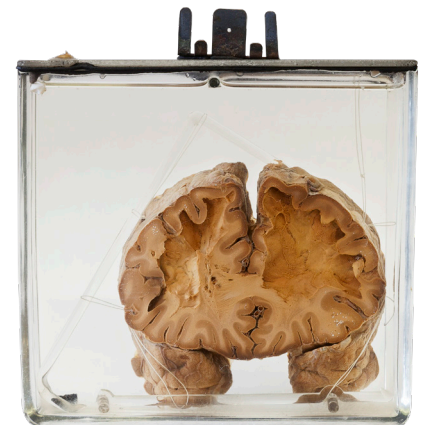


Immortalizing the Mortal: Art in the Service of Death

For the second year, the *Immortalizing the Mortal* event was held during the evening of May 31, 2018. Nine students contributed poems and art work on the subject of lobotomy. The procedure and its pathological and psychological consequences were briefly discussed, following which the students presented and discussed their artistic interpretations.

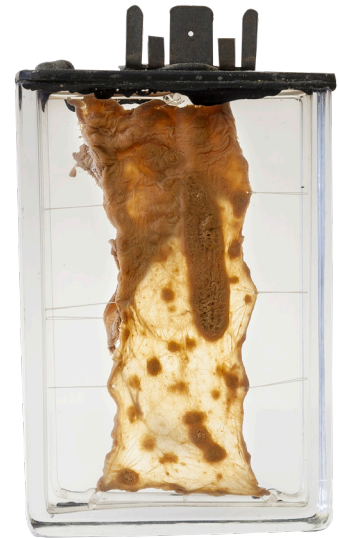Rt: Frontal lobe slice showing loss of white matter. 49 year-old man who died six months post surgery.

Below: Storyboard representation of a fictional conversation with the patient pre- and post-lobotomy. Rachel Medvedev. Physical Therapy Candidate, 2019.



The Pathological Collection Lost and Found Department

During the 2013 move of pathological material from the Duff Medical Building to the Strathcona Building, a number of noteworthy specimens were discovered. The one shown here was obtained in 1908 and consists of an 11 cm length of small intestine showing focal ulceration and hyperplastic lymphoid tissue (Peyer's patches), characteristic of infection by *Salmonella* (typhoid fever). This disease was endemic in Montreal in the early 20th century. Two outbreaks were particularly noteworthy. At the beginning of December 1909, the city's five public hospitals had admitted more than 3000 affected patients and were unable to accept any more. The Montreal Typhoid Emergency Hospital, created in an abandoned building on Aqueduct Street, offered rent-free by Northern Electric, opened on Jan. 4, 1910 to house the overflow. It closed three months later after the epidemic abated. During this time, the Montreal Children's Hospital also created an isolation ward to care for the many affected children. A second epidemic in 1927, probably transmitted by unpasteurized milk, resulted in approximately 5,000 cases and 538 deaths. After this outbreak had run its course, Montreal developed its first health code focused on prepared or served food.



Become a Friend

Membership in the Friends of the Maude Abbott Medical Museum is open to anyone who is interested in the museum and the history of medicine. Your support will allow us to preserve our rich collection and make it available to others for teaching and research. Application can be made by contacting us at medicalmuseum.med@mcgill.ca

Thank you!

Special thanks are due to our Friends for their generous donations. Your moral and financial support will have an important impact on new exhibits and the displays we are developing during the coming year.

Maude Abbott Medical Museum



Musée médical Maude-Abbott



If you would prefer to receive this newsletter by email, please let us know at: medicalmuseum.med@mcgill.ca

Maude Abbott Medical Museum Newsletter Volume 3, No 1, Fall 2018 © 2018 Maude Abbott Medical Museum

We are always happy to hear from you. Please send your comments to Joan O'Malley
Room 2/38B
Strathcona Anatomy and Dentistry Building
3640 University Street
Montreal, Quebec H3A 0C7

Email: medicalmuseum.med@mcgill.ca
URL: <https://www.mcgill.ca/medicalmuseum>

Editor: Dr. Richard Fraser
Graphic Design: Joan O'Malley
Printing: Rubiks.ca
