

# Continuous Peripheral Nerve Blocks in the Hospital and at Home

Brian M. Ilfeld, MD, MS

## KEYWORDS

- Continuous peripheral nerve block
- Perineural local anesthetic infusion • Postoperative analgesia
- Continuous catheter

A single-injection peripheral nerve block using long-acting local anesthetic will provide analgesia for 12 to 24 hours; however, many surgical procedures result in pain that lasts far longer. One relatively new option is a continuous peripheral nerve block (CPNB), also called “perineural local anesthetic infusion.” This technique involves the percutaneous insertion of a catheter directly adjacent to the peripheral nerve(s) supplying the surgical site (as opposed to a “wound” catheter placed directly at a surgical site). Infusing local anesthetic via the perineural catheter then provides potent, site-specific analgesia. This method was first described in 1946 using a cork to stabilize a needle placed adjacent to the brachial plexus divisions to provide a “continuous” supraclavicular block.<sup>1</sup> Subsequently, Sarnoff and Sarnoff<sup>2</sup> described the use of an indwelling plastic catheter allowing repeated boluses of local anesthetic along the phrenic nerve to treat intractable hiccups. Additional sporadic techniques and applications of CPNB were reported,<sup>3–5</sup> but it was not until the 1990s that technological advances in needle technology, placement techniques (eg, nerve stimulators), catheter design, and infusion pump mechanics presaged a plethora of CPNB research activity.<sup>6,7</sup>

## INDICATIONS AND SELECTION CRITERIA

Because not all patients desire, or are capable of accepting, the extra responsibility that comes with the catheter and pump system, appropriate patient selection is crucial

---

**Funding:** This work was supported by the Department of Anesthesiology, University of California San Diego, San Diego, California.

**Conflict of Interest:** Dr Ilfeld has received research funding from multiple companies that manufacture and/or distribute portable infusion pumps and perineural catheters. No company had any input into any aspect of this article's preparation.

Department of Anesthesiology, University of California San Diego, 200 West Arbor Drive, MC 8770, San Diego, CA 92103-8770, USA

*E-mail address:* [bilfeld@ucsd.edu](mailto:bilfeld@ucsd.edu)

Anesthesiology Clin 29 (2011) 193–211

doi:[10.1016/j.anclin.2011.04.003](https://doi.org/10.1016/j.anclin.2011.04.003)

[anesthesiology.theclinics.com](http://anesthesiology.theclinics.com)

1932-2275/11/\$ – see front matter © 2011 Elsevier Inc. All rights reserved.

for safe CPNB, particularly in the ambulatory environment.<sup>8</sup> Patients with known hepatic or renal insufficiency are often excluded in an effort to avoid local anesthetic toxicity.<sup>9</sup> For interscalene and cervical paravertebral infusions that may affect the phrenic nerve and ipsilateral diaphragm function,<sup>10</sup> particular caution is warranted in patients with heart or lung disease who may not be able to compensate for mild hypercarbia and/or hypoxia.<sup>11</sup>

Because there are inherent risks with any invasive procedure,<sup>12,13</sup> most practitioners limit the use of CPNB to patients expected to have postoperative pain lasting longer than 12 to 24 hours that is not easily managed with oral analgesics. However, CPNB has been used following *mildly* painful procedures to decrease opioid requirements and related side effects.<sup>14,15</sup> There are few published data on the use of various catheter locations for specific surgical procedures, although individual recommendations are available (**Table 1**).<sup>16</sup> In general, axillary, cervical paravertebral (CPVB), infraclavicular, or supraclavicular infusions are used for surgical procedures involving the hand, wrist, forearm, or elbow; interscalene, CPVB, and intersternocleidomastoid catheters are used for surgical procedures involving the shoulder or proximal humerus; thoracic paravertebral catheters are used for breast or other thoracic/abdominal procedures; psoas compartment catheters are used for hip surgery; fascia iliaca, femoral, and psoas compartment catheters are used for knee or thigh procedures; and popliteal/subgluteal catheters are used for surgical procedures of the leg, ankle, or foot.

**EQUIPMENT AND TECHNIQUES**

***Techniques and Approaches***

Although there are numerous catheter-placement techniques reported, from ultrasound<sup>17,18</sup> and fluoroscopic guidance<sup>19</sup> to nerve stimulation<sup>20</sup> and listening for a fascial “click,”<sup>21</sup> few studies specifically address the question of which technique is optimal for the various catheter locations. Although many proponents voice firm opinions based on their experience and/or imaging studies, few clinical data exist. Therefore, the optimal approach for catheter placement at each anatomic location remains unknown and deserves future study.

***Stimulating versus Nonstimulating Catheters***

One common technique involves giving a bolus of local anesthetic via an insulated needle (attached to a nerve stimulator) to provide a surgical block, followed by the introduction of a “nonstimulating” catheter.<sup>22</sup> However, in using this technique, it is

Table 1 Common catheter insertions for surgical procedures on various anatomic locations (recommended site underlined)	
Surgical Procedure Location	Catheter Insertion Location
Shoulder or proximal humerus	<u>Interscalene</u> , intersternocleidomastoid, cervical paravertebral
Distal humerus, elbow, forearm, hand	Supraclavicular, <u>infraclavicular</u> , axillary
Breast, thoracic, or abdominal incisions	<u>Paravertebral</u>
Hip	<u>Psoas compartment (posterior lumbar plexus)</u> , fascia iliaca, and femoral
Thigh and knee	Fascia iliaca and <u>femoral</u>
Leg, ankle, and foot	Subgluteal and <u>popliteal sciatic</u>

possible to provide a successful surgical block, but inaccurate catheter placement.<sup>23</sup> Some practitioners first insert the catheter and then administer a bolus of local anesthetic via the catheter in an effort to avoid this problem, with a reported failure rate of 1% to 8%.<sup>24,25</sup> Alternatively, catheters that deliver current to their tips have been developed in an attempt to improve initial placement success rates.<sup>7</sup> These catheters provide feedback on the positional relationship of the catheter tip to the target nerve before local anesthetic dosing.<sup>26</sup> There are limited data suggesting that stimulating catheters may, under some conditions, provide superior analgesia.<sup>27</sup> Regardless of the equipment/technique used, a “test dose” of local anesthetic with epinephrine should be administered via the catheter in an effort to identify intrathecal, epidural, or intravascular placement before infusion initiation. Ultrasound guidance is quickly gaining adherents, and may soon render the “stimulating versus nonstimulating” catheter debate moot.

### ***Ultrasound-Guided Catheter Insertion***

For ultrasound-guided procedures, the term “long axis” is used when the length of a nerve is within the ultrasound beam, compared with “short axis” when viewed in cross section.<sup>18</sup> A needle inserted with its length within a 2-dimensional ultrasound beam is described as “in plane,” whereas a needle inserted across a 2-dimensional ultrasound beam is termed “out of plane.”<sup>18</sup> Catheter insertion may be achieved with 3 various techniques, which are described in the following sections.

#### ***Needle out-of-plane, nerve in short-axis approach***

Potential benefits of this approach include a generally familiar parallel needle-to-nerve trajectory used with traditional nerve stimulation techniques (and also vascular access); and the catheter may theoretically remain in closer proximity to the nerve, even when threaded more than a centimeter past the needle tip, because the needle is parallel to the target nerve.<sup>28,29</sup> However, a disadvantage of this technique is the relative inability to visualize the advancing needle tip,<sup>28,30</sup> which some speculate increases the likelihood of unwanted contact with nerves, vessels, peritoneum, pleura, or even meninges.<sup>31</sup> Practitioners often use a combination of tissue movement and “hydro-location,” in which fluid is injected and the resulting expansion infers the needle tip location (either with or without color Doppler flow).<sup>30,32</sup> It has been suggested that for superficial catheters (eg, interscalene and femoral), the consequent “longitudinal” orientation of needle with nerve makes precise visualization of the needle tip less critical, as the needle tip tends to remain relatively close to the nerve if the needle tip is advanced beyond the ultrasound beam. However, for deeper nerves, this technique is not as straightforward as guiding the needle tip to a target nerve, as in the in-plane technique, and may be more difficult to master (and, at times, nearly impossible).<sup>33,34</sup>

#### ***Needle in-plane, nerve in short-axis approach***

Because this view allows for easier nerve identification, this is the most-frequently published *single*-injection peripheral nerve block orientation.<sup>18</sup> The needle tip location can be more easily identified relative to the target nerve when the long axis of the needle is inserted within the ultrasound plane. If the initial local anesthetic bolus is placed through the needle, its spread may be directly observed and needle tip adjustments made, when necessary. However, the perineural catheter tends to bypass the nerve during insertion, given the perpendicular orientation of the block needle and target nerve,<sup>35</sup> although there are certain anatomic locations that will often allow a catheter to be passed and remain perineural.<sup>36,37</sup> Some practitioners have advocated either passing the catheter a minimal distance past the needle tip, or advancing the catheter further initially and

then, after needle removal, retracting the catheter such that its orifice(s) lies a minimal distance ( $<2$  cm) past the original needle tip position.<sup>28</sup> Some advocate using an extremely flexible perineural catheter in an attempt to keep the catheter tip in close proximity to the target nerve if the catheter is inserted more than a minimal distance.<sup>38,39</sup> Still others describe reorienting the needle from an in-plane to a more parallel trajectory and inserting a stimulating catheter to better monitor catheter tip location.<sup>40</sup>

There are multiple benefits of the needle in-plane, nerve in short-axis approach. Practitioners may learn only one technique because it may be used for both single-injection and catheter insertion procedures. In addition, it may be used for nearly all anatomic catheter locations, even for deeper target nerves.<sup>41</sup> There are disadvantages of this approach as well. They include new needle entry sites relative to the nerve compared with more traditional nerve-stimulation modalities that typically use a parallel needle-to-nerve insertion; challenges keeping the needle shaft in-plane<sup>42</sup>; difficult needle tip visualization for relatively deep nerves<sup>33,34</sup>; and, as noted previously, the catheter tip may bypass the target nerve given the perpendicular orientation of the needle and nerve.<sup>35</sup> If an extremely flexible catheter is used in an attempt to minimize this issue, it is sometimes difficult to thread past the tip of the placement needle.<sup>38,39</sup>

### ***Needle in-plane and nerve in long-axis approach***

Superficially, this technique appears to have the benefits of both previously described approaches, with few limitations. The nerve can be viewed along with the needle shaft/tip, and the catheter monitored as it exits the needle parallel to the target nerve. The difficulty lies in keeping 3 structures—the needle, nerve, and catheter—in the ultrasound plane.<sup>43,44</sup> In addition, to view the nerve in long axis, the nerve itself must be relatively straight, and there can be only one target nerve as opposed to multiple trunks or cords, as found within the brachial plexus. Evidence of this technique's difficulties may be found in the scarcity of reports.<sup>43–45</sup>

Limitations on the length of this article precludes a discussion of multiple additional ultrasound-related issues, such as transducer selection, the concomitant use of nerve stimulation (an important tool in a subset of patients),<sup>46</sup> and various methods for catheter tip localization.<sup>47</sup> Although many proponents voice firm opinions based on their personal experience, few clinical data exist comparing aspects of any one placement technique with another.

## **INFUSATES**

Currently, there is insufficient information to determine if there is an optimal local anesthetic for CPNB. Although levobupivacaine and shorter-acting agents have been used, most investigators use bupivacaine or ropivacaine. Studies involving one may not be applied to another because these local anesthetics have varying durations of action.<sup>48</sup> One trial involving interscalene infusion found that ropivacaine 0.2% and bupivacaine 0.15% provide similar analgesia, but ropivacaine was associated with better preservation of strength in the hand and less paresthesia in the fingers,<sup>48</sup> although other studies comparing ropivacaine and either levobupivacaine<sup>49</sup> or bupivacaine<sup>15</sup> found no difference. Given that the equipotent local anesthetic concentrations within the peripheral nervous system remain undetermined, evaluation of comparisons is problematic. Based on preliminary evidence, it appears that the total local anesthetic dose, as opposed to concentration or delivery rate, mainly determines infusion effects,<sup>50</sup> although the data are somewhat conflicting.<sup>51–54</sup> For ropivacaine and bupivacaine, concentrations between 0.1% and 0.2% and 0.1% and 0.125% are most commonly used, respectively. Regarding additives, opioids and epinephrine have been used,<sup>55,56</sup> but there are currently insufficient published data to draw any conclusions regarding

the safety of the former<sup>57</sup> or the efficacy of the latter.<sup>58,59</sup> And although clonidine has been often added to long-acting local anesthetic in perineural infusions,<sup>60–65</sup> 3 randomized, double-masked, placebo-controlled trials have failed to reveal any clinically relevant benefits.<sup>66–68</sup>

## LOCAL ANESTHETIC DELIVERY STRATEGIES

Unfortunately, there is no single optimal local anesthetic delivery regimen.<sup>51–53,61,63,64,69–75</sup> In general, providing a basal infusion minimizes breakthrough pain and sleep disturbances.<sup>64,69,70,75</sup> Adding patient-controlled bolus doses improves analgesia, decreases opioids and related side effects, and allows for a lower basal infusion rate,<sup>69,70</sup> although there are exceptions.<sup>61,75</sup> Lowering the basal infusion rate may decrease the risk of patient falls for catheters that influence quadriceps femoris strength, such as femoral, fascia iliaca, and psoas compartment infusions (Brian Ilfeld, MD, MS, unpublished data, 2010). Unfortunately, insufficient information is available to base recommendations on the optimal basal rate, bolus volume, and lockout period, which accounts for the many variables that may effect these values (eg, catheter type, location, surgical procedure). Until recommendations based on prospectively collected data are published, practitioners may consider using the following *initial* settings with long-acting local anesthetics: basal rate of 4 to 8 mL/h (low end of range for lower extremity infusions), bolus volume of 2 to 5 mL, and lockout duration of 20 to 60 minutes. In addition, it is of great value to be able to adjust the basal infusion rate, as there is no way to predict each patient's requirements in advance, and surgical pain decreases as time progresses.<sup>76</sup>

## AMBULATORY INFUSION

Although many issues are similar between hospital-based and outpatient CPNB, such as catheter insertion techniques, ambulatory perineural infusion poses some distinct challenges requiring some unique solutions. For example, time pressures are often more intense at high-turnover ambulatory centers, and ultrasound-guided catheter insertion not only decreases the median/mean time for placement across all subjects, but also essentially eliminates the few patients who require more than 10 minutes for catheter insertion (unlike nerve-stimulation techniques).<sup>39,41,77,78</sup> In addition, secondary block failure may occur following discharge, so identifying inaccurately placed perineural catheters during insertion becomes even more critical.<sup>8,23</sup> As noted previously, but deserving special emphasis for ambulatory infusions because not all patients desire, or are capable of accepting, the extra responsibility that comes with the catheter and pump system, appropriate patient selection is crucial for safe CPNB.<sup>8</sup> Patients with known hepatic or renal insufficiency are often excluded in an effort to avoid local anesthetic toxicity.<sup>9</sup> For interscalene and cervical paravertebral infusions that may affect the phrenic nerve and ipsilateral diaphragm function,<sup>10</sup> particular caution is warranted in obese individuals and patients with heart or lung disease who may not be able to compensate for mild hypercarbia and/or hypoxia.<sup>11</sup>

### ***Infusion Pump Selection***

In general, electronic infusion pumps provide highly accurate (90%–100% expected) and consistent ( $\pm 5\%$  baseline) basal rates over the entire infusion duration.<sup>79–82</sup> Elastomeric devices generally provide a higher-than-expected basal rate initially (110%–125% expected), returning to their expected rate within 2 to 12 hours, and again increasing to a higher rate before reservoir exhaustion.<sup>8</sup> Similarly, spring-powered pumps initially provide a higher-than-expected basal rate (115%–135% expected),

which steadily decreases to a lower-than-expected rate (70%–75% expected) by reservoir exhaustion.<sup>8</sup> Currently, there are insufficient published data to determine the clinical situations in which the typical basal rate variation of nonelectronic pumps would be clinically relevant. As noted previously, a variable basal rate and patient-controlled bolus dose provide perineural infusion benefits, and are probably even more important in the ambulatory setting: by providing bolus doses, the basal rate may be decreased, greatly increasing the duration of infusion before reservoir exhaustion. In addition, as patients' surgical pain resolves with time, the basal rate may be decreased, also enabling the maximum infusion duration before reservoir exhaustion.<sup>76</sup> Reservoir volume should usually be at least 400 and 500 mL for lower-extremity and upper-extremity infusions, respectively, providing 2 to 3 days of analgesia. Electronic infusion pumps make a "click" every time they infuse (often more than twice per minute), which may prove disturbing to patients trying to sleep. Last, there are some electronic infusion pumps that have internal batteries that may not be removed. It is illegal in some locations (eg, the states of California and New York) to dispose of such pumps in the standard garbage, and special pump-delivery protocols must be set up for outpatients.

---

### **Discharge**

Patients and their caretakers should be educated regarding the infusion pump and catheter system before discharge, because most patients have some degree of postoperative cognitive dysfunction. Both verbal *and written* instructions should be provided, along with contact numbers for health care providers who are available throughout the infusion duration. Along with standard postoperative outpatient instructions, topics reviewed usually include infusion pump instructions, expectations regarding surgical block resolution, breakthrough pain treatment, limb protection, bathing instructions, explicit direction to avoid driving, education that leakage at the catheter site is not dangerous (use hand towels to absorb fluid), and catheter removal plan.<sup>8</sup>

It is currently impossible to accurately *predict* which patients will require oral opioids. Therefore, a prescription for oral analgesics should be provided to all patients, and the importance of filling the prescription immediately after leaving the surgical center should be emphasized. A period of inadequate analgesia may result if patients wait to fill the prescription until after they have determined if oral analgesics are required. Patients discharged home must be able to ambulate. Therefore, discharge with a lower-extremity peripheral nerve block remains controversial. Although there is published evidence that discharge with an insensate extremity following a single-injection nerve block results in minimal complications,<sup>83</sup> there are multiple case reports of falls during lower-extremity CPNB,<sup>84–87</sup> and the specific incidence remains unknown. Therefore, conservative management may be optimal and some investigators have recommended that patients avoid using their surgical limb for weight bearing.<sup>8</sup>

---

### **Home Care**

Practitioners should consider documenting each patient contact, as is standard of care for inpatients. The optimal frequency of contact with ambulatory patients is currently unknown, and probably is dependent on multiple factors, such as patient comorbidities and surgical procedure. Multiple investigators have discharged patients with instructions to call with any questions or concerns; others have suggested that patients be contacted daily by telephone; whereas still others have provided twice-daily home nursing visits in addition to telephone calls. Investigators have reported catheter removal by various techniques: some discharge patients with written instructions, others have insisted on a health care provider performing this procedure, whereas others have patients' caretakers (or occasionally the patients themselves) remove

the catheters with instructions given by a provider over the telephone. Although there are no data documenting the superiority of any one technique, one survey revealed that with instructions given by phone, 98% of patients felt comfortable removing their catheter at home.<sup>88</sup> Of note, only 4% would have preferred to return for a health care provider to remove the catheter, and 43% responded that they would have felt comfortable with exclusively written instructions. The presence of a blue/silver catheter tip identified by the person removing the catheter confirms complete removal (depending on catheter design), and should be documented in the medical record.

## POTENTIAL BENEFITS

Multiple randomized, controlled studies involving patients scheduled for moderately painful surgical procedures demonstrate the potent analgesia CPNB provides.<sup>60–62,89–97</sup> Improved analgesia leads to dramatic decreases in required supplemental opioids, opioid-related side effects, and sleep disturbances, while simultaneously increasing patient satisfaction.<sup>89,90,92</sup> In addition, one study reported a decreased time to adequate ambulation and optimization of daily activities using ambulatory CPNB compared with intravenous opioids.<sup>98</sup> Continuous interscalene and femoral nerve blocks following shoulder and knee arthroplasty result in an accelerated resumption of tolerated passive joint range-of-motion<sup>91,99,100</sup>; in some cases<sup>60,62</sup> leading to shorter hospitalization.<sup>91,99</sup> Providing ambulatory continuous femoral and psoas compartment nerve blocks decreases the time until discharge readiness following knee and hip arthroplasty, although an increased incidence of patient falls in patients receiving ropivacaine versus saline through their catheters is cause for caution before instituting early discharge.<sup>85–87</sup> Nonetheless, ambulatory shoulder arthroplasty and 23-hour-stay knee and hip arthroplasty have been reported using ambulatory continuous interscalene, femoral, and psoas compartment nerve blocks.<sup>101–103</sup> Should early discharge be allowed following joint arthroplasty, hospitalization-related costs may be decreased.<sup>103</sup> Although post-knee arthroplasty inflammation is decreased after a continuous femoral nerve block,<sup>104</sup> the continuous block has failed to produce major improvements in long-term outcomes such as decreased chronic pain and improved health-related quality of life.<sup>105,106</sup>

## POTENTIAL RISKS/COMPLICATIONS

Two of the largest prospective investigations to date involving more than 2100 patients combined suggest that the incidence of related complications is very low—at least as low as, if not lower than, single-injection techniques.<sup>24,107</sup> Smaller studies involving continuous infraclavicular and popliteal blocks suggest a similar incidence of complications.<sup>25,108</sup>

### *Inaccurate Catheter Placement*

The initial bolus of local anesthetic placed via the needle may produce a successful nerve block; but the catheter tip may be inaccurately placed, resulting in what has been called “secondary block failure.”<sup>22,23</sup> The incidence of this complication is 0% to 40%,<sup>22,23</sup> and presumably is dependent on many factors, including the experience of the practitioner, equipment, and technique, as well as patient factors, such as body habitus.<sup>109,110</sup> Practitioners have first inserted the catheter and then injected the initial local anesthetic via the catheter in an effort to decrease the chances of secondary block failure.<sup>24,26,69,70,75</sup> If a surgical block does not develop, the catheter may be replaced. Ultrasound guidance may dramatically alter the incidence of catheter



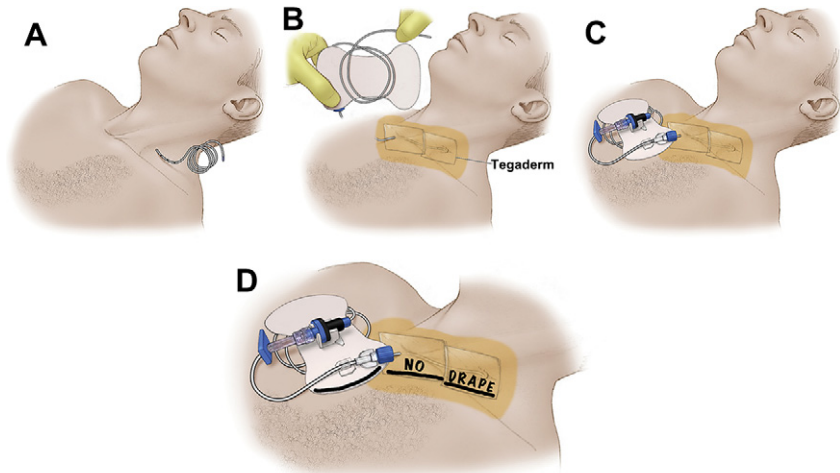
misplacement, but additional evidence must be collected to allow definitive conclusions.<sup>39,41,77,78</sup>

### **Catheter Dislodgement**

Inadvertent catheter dislodgement is one of the most common complications during perineural infusion, with a reported incidence between 0% and 30%.<sup>8</sup> To maximize patient benefits, every effort to optimally secure the catheter must be made, especially in ambulatory patients. Measures have included the use of sterile liquid adhesive (eg, benzoin), sterile tape (eg, "Steri-Strips"), securing of the catheter-hub connection with either tape or specifically designed devices (eg, "Statlock"), subcutaneous tunneling of the catheter, and the use of 2-octyl cyanoacrylate glue (Fig. 1).<sup>111</sup> Using a combination of these maneuvers, 1-week catheter retention rates of 95% to 100% are possible.<sup>101,112</sup>

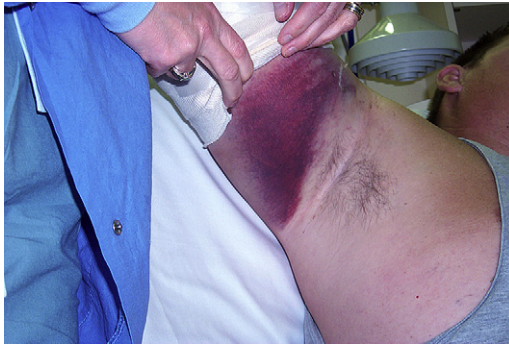### **Vascular Puncture/Hematoma**

Vascular puncture and subsequent hematoma formation is certainly a well-known complication of single-injection peripheral nerve blocks, but may be a more significant occurrence when placing a perineural catheter because the needle gauge is often larger to allow for intraluminal catheter insertion (Fig. 2). Using nerve stimulation and an insulated needle, the incidence of this complication is reportedly between 0% and 11%, and most likely is influenced significantly by such variables as the anatomic block location and needle/catheter design.<sup>22,70,107,108,113,114</sup> However, the addition of



**Fig. 1.** Securing a perineural catheter. (A) An interscalene catheter placed using nerve stimulation from the anterolateral technique following needle removal. Note that any hair where an adhesive will be applied has been clipped before sterilization for the catheter insertion. (B) Benzoin (medical adhesive) is placed beyond the borders of where the occlusive dressings will be placed, slightly overlapping occlusive dressings are applied, and excess catheter is wound on the back of an anchoring device. (C) The anchoring device is placed slightly overlapping the occlusive dressing, which will permit easy removal of all 3 adhesives on infusion discontinuation. (D) Surgical drapes are often inadvertently placed across clear occlusive dressings, which then remove the dressings following the surgical procedure, contaminating (or dislodging) the catheter. Outlining the dressings and communicating with the surgeon ("no drape") will help avoid this scenario.





**Fig. 2.** A hematoma following axillary artery puncture with a 17-gauge needle during a nerve stimulation guided infraclavicular block and perineural catheter insertion. The hematoma resolved within 6 weeks, without negative sequelae.

ultrasound guidance may significantly decrease the risk of entering a vessel.<sup>39,41,77,78</sup> Following interscalene catheter insertion, a prolonged Horner syndrome owing to neck hematoma has been reported, but is very rare.<sup>12</sup> Although a hematoma may require weeks for resolution (months for a Horner syndrome), practitioners and patients should be reassured with the multiple case reports of complete neural recovery following hematoma resolution.<sup>12,113,115,116</sup> If vascular puncture occurs, it is still possible to successfully place a perineural catheter using nerve stimulation following a period of direct pressure, although a resulting hematoma will conduct electrical current and may decrease the ability to stimulate the target nerve with subsequent attempts.<sup>70</sup> Of note, clinically significant hematoma formation has been reported in patients with a psoas compartment catheter who received low molecular weight heparin (LMWH) for anticoagulation.<sup>115,116</sup> These occurrences have led some practitioners to manage patients with a psoas compartment catheter in much the same way as those having neuraxial block when thromboprophylaxis is ordered,<sup>115</sup> although others have questioned this practice.<sup>117</sup> The Second American Society of Regional Anesthesia consensus statement on neuraxial anesthesia and anticoagulation notes that, “conservatively, the [recommendations]... may be applied to plexus and peripheral techniques. However, this may be more restrictive than necessary,” and “additional information is needed to make definitive recommendations.”<sup>118(p192)</sup> Few substantial revisions to these recommendations were included in the more-recent Third Consensus Statement.<sup>119</sup>

### ***Delayed Local Anesthetic Toxicity***

Patients have reported early symptoms of local anesthetic toxicity during CPNB (eg, perioral numbness) that resolved with infusion termination.<sup>120,121</sup> Although practitioners should remain alert to the possibility of this complication, it remains an extraordinarily rare event. The maximum safe doses for the long-acting local anesthetics as well as the incidence of systemic toxicity are unknown; however, infusing 40 mg or less of ropivacaine each hour has resulted in a remarkably rare incidence of toxicity events, even over the course of multiple weeks.<sup>122</sup> Of note, providing patients with the ability to self-administer bolus doses decreases local anesthetic consumption.<sup>61,63,64,69–71,73–76,123</sup> Related to this, investigators often exclude patients from an ambulatory or long-duration CPNB with known hepatic or renal insufficiency in an effort to avoid local anesthetic toxicity.<sup>9,89,90,92</sup>

### ***Nerve Injury***

---

Nerve injury is a recognized complication following placement of both single-injection and CPNB, presumably related to needle trauma and/or subsequent local anesthetic/adjuvant neurotoxicity.<sup>124</sup> Current evidence suggests that the incidence of neural injury from a perineural catheter and ropivacaine (0.2%) infusion is no higher than following single-injection regional blocks.<sup>24,25,113,121</sup> There are 2 case reports of interscalene perineural catheters possibly resulting in brachial plexus irritation.<sup>13</sup> In both of these cases, repeated boluses of 0.25% bupivacaine had been injected over a period of days, and patient discomfort ceased upon removal of the catheters.<sup>13</sup> There is also evidence that in diabetes, the risk of local anesthetic-induced nerve injury is increased.<sup>125</sup>

### ***Infection***

---

Clinically relevant catheter-related infection remains an uncommon occurrence, even though catheter site bacterial colonization is relatively common.<sup>107,113,126,127</sup> In more than 2700 patients combined, infection rates varied from 0% to 3%, with one psoas compartment abscess forming following femoral CPNB in prospective investigations of interscalene,<sup>24,113</sup> posterior popliteal,<sup>25</sup> and multiple-site<sup>107</sup> catheters. In these few cases, all infections completely resolved within 10 days, and there has never been a reported case of a permanent deficit caused by a catheter infection.<sup>107,128</sup> Although there are cases of prolonged infusions lasting many weeks,<sup>122</sup> limiting catheter use to 3 to 4 days may further decrease the incidence of this complication,<sup>107</sup> and practitioners should balance the need for analgesia with the risk of infection.<sup>127</sup> Although data specific for perineural catheters are lacking, current guidelines recommend treating catheter insertion with the same sterile precautions as central lines, including use of a sterilization solution (eg, chlorhexidine) at the insertion site, sterile gloves, and drape, as well as a hat and mask. Although some practitioners wear a sterile gown during catheter insertion, this addition is currently somewhat controversial.

### ***Perineuraxis Injection***

---

It is possible to cannulate the epidural<sup>129–131</sup> or intrathecal<sup>132</sup> spaces when placing a catheter near the neuraxis, as with the psoas compartment and interscalene locations. Potentially catastrophic is the injection of local anesthetic, which may result in unconsciousness and extreme hypotension requiring aggressive resuscitation. As with intravascular catheter placement, it is possible to accurately inject the initial bolus of local anesthetic via the needle, followed by cannulation of the epidural,<sup>129</sup> intrathecal,<sup>132</sup> and even intrapleural spaces with the catheter.<sup>133</sup> Of note, when working close to the neuraxis, it is possible to get epidural local anesthetic spread even with an accurately placed perineural catheter, resulting in a sympathectomy and possible hypotension. Whether ultrasound guidance will result in a decreased incidence of such complications is currently unknown, given the relatively recent advent of ultrasound-guided perineural catheter insertion.

### ***Catheter Migration***

---

Spontaneous migration into adjacent anatomic structures following a documented correct placement has been described in only one patient.<sup>107</sup> Possible theoretical complications from such an incident include intravascular or interpleural migration resulting in local anesthetic toxicity, and epidural/intrathecal migration when using an interscalene, intersternocleidomastoid, paravertebral, or psoas compartment

catheter. Of note, it is possible to accidentally position the catheter tip in the epidural space (and presumably other structures) following partial catheter withdrawal.<sup>129</sup>

### ***Pulmonary Complications***

For infusions that may affect the phrenic nerve and ipsilateral diaphragm function (eg, interscalene or cervical paravertebral catheters), caution is warranted, as interscalene CPNBs have been shown to cause frequent ipsilateral diaphragm paralysis.<sup>11</sup> Although the effect on overall pulmonary function may be minimal for relatively healthy patients,<sup>10</sup> a case of clinically relevant lower lobe collapse in a patient with an interscalene infusion at home and 2 cases of acute respiratory failure have occurred.<sup>107,134</sup>

### ***Catheter Knotting and Retention***

Several case reports of catheter retention have been published, although the overall incidence of this complication is unknown.<sup>70,135–137</sup> The most common etiology is knot formation below the skin or fascia, and has been reported in fascia iliaca,<sup>135</sup> femoral,<sup>136</sup> and psoas compartment catheters.<sup>137</sup> Two of these cases required surgical exploration for catheter removal<sup>136,137</sup>; however, removal of a knotted fascia iliaca catheter was achieved without surgical intervention with simple hip flexion.<sup>135</sup> In all of these cases, the catheter had been advanced more than 5 cm past the needle tip. Advancing the catheter more than 3 to 5 cm is often attempted in an effort to decrease the risk of dislodgement, or to “thread” the catheter tip toward the lumbar plexus when using the femoral or fascia iliaca insertion points.<sup>138</sup> However, retention rates of 95% to 100% have been reported using a maximum distance of 5 cm<sup>66,67,69,70,75,89,90,92</sup>, and in the absence of using a catheter-over-wire Seldinger technique,<sup>61–63,139,140</sup> the catheter tip rarely reaches the lumbar plexus following a femoral insertion.<sup>138</sup> The available data suggest that insertion greater than 5 cm is unnecessary and may increase the knotting risk, although there is no consensus regarding the optimal distance of catheter insertion.<sup>135</sup>

### ***Catheter Shearing***

It is possible to “shear off” a segment of catheter if, following insertion past the needle tip, the catheter itself is withdrawn back into the needle. Therefore, this maneuver should be attempted only when using needle/catheter combinations that have been specifically designed for catheter withdrawal. And when using specifically designed needle/catheter combinations, such as with some stimulating catheters, catheter withdrawal should cease with any resistance, and the needle itself retracted until the catheter resistance resolves.<sup>67,69,70,75,141</sup> In one reported case, a 6-cm femoral catheter fragment was sheared off and remained in situ for 1 week, causing persistent pain of the ipsilateral groin, thigh, and knee.<sup>142</sup> Despite an embedded radiopaque strip, the catheter fragment could not be visualized with plain radiographs. However, a computerized tomographic scan did localize the fragment and the femoral nerve neuralgia resolved in the week following surgical extraction of the fragment.<sup>142</sup> In an additional case, an axillary catheter fragment was diagnosed with ultrasonography and surgically extracted.<sup>121</sup> In all of the case reports of retained catheters/fragments, no patient experienced persistent symptoms following removal.<sup>70,121,141,142</sup>

## **REFERENCES**

1. Ansbro FP. A method of continuous brachial plexus block. *Am J Surg* 1946;71: 716–22.

2. Sarnoff SJ, Sarnoff LC. Prolonged peripheral nerve block by means of indwelling plastic catheter. Treatment of hiccup. *Anesthesiology* 1951;12:270–5.
3. Cheeley LN. Treatment of peripheral embolism by continuous sciatic nerve block. *Curr Res Anesth Analg* 1952;31:211–2.
4. Manriquez RG, Pallares V. Continuous brachial plexus block for prolonged sympathectomy and control of pain. *Anesth Analg* 1978;57:128–30.
5. DeKrey JA, Schroeder CF, Buechel DR. Continuous brachial plexus block. *Anesthesiology* 1969;30:332.
6. Steele SM, Klein SM, D'Ercole FJ, et al. A new continuous catheter delivery system. *Anesth Analg* 1998;87:228.
7. Boezaart AP, de Beer JF, du TC, et al. A new technique of continuous interscalene nerve block. *Can J Anaesth* 1999;46:275–81.
8. Ilfeld BM, Enneking FK. Continuous peripheral nerve blocks at home: a review. *Anesth Analg* 2005;100:1822–33.
9. Denson DD, Raj PP, Saldanha F, et al. Continuous perineural infusion of bupivacaine for prolonged analgesia: pharmacokinetic considerations. *Int J Clin Pharmacol Ther Toxicol* 1983;21:591–7.
10. Borgeat A, Perschak H, Bird P, et al. Patient-controlled interscalene analgesia with ropivacaine 0.2% versus patient-controlled intravenous analgesia after major shoulder surgery: effects on diaphragmatic and respiratory function. *Anesthesiology* 2000;92:102–8.
11. Pere P. The effect of continuous interscalene brachial plexus block with 0.125% bupivacaine plus fentanyl on diaphragmatic motility and ventilatory function. *Reg Anesth* 1993;18:93–7.
12. Ekatothramis G, Macaire P, Borgeat A. Prolonged Horner syndrome due to neck hematoma after continuous interscalene block. *Anesthesiology* 2001;95:801–3.
13. Ribeiro FC, Georgousis H, Bertram R, et al. Plexus irritation caused by interscalene brachial plexus catheter for shoulder surgery. *Anesth Analg* 1996;82:870–2.
14. Rawal N, Axelsson K, Hylander J, et al. Postoperative patient-controlled local anesthetic administration at home. *Anesth Analg* 1998;86:86–9.
15. Rawal N, Allvin R, Axelsson K, et al. Patient-controlled regional analgesia (PCRA) at home: controlled comparison between bupivacaine and ropivacaine brachial plexus analgesia. *Anesthesiology* 2002;96:1290–6.
16. Boezaart AP. Perineural infusion of local anesthetics. *Anesthesiology* 2006;104: 872–80.
17. Guzeldemir ME, Ustunsoz B. Ultrasonographic guidance in placing a catheter for continuous axillary brachial plexus block. *Anesth Analg* 1995;81:882–3.
18. Gray AT. Ultrasound-guided regional anesthesia: current state of the art. *Anesthesiology* 2006;104:368–73.
19. Pham-Dang C, Meunier JF, Poirier P, et al. A new axillary approach for continuous brachial plexus block. A clinical and anatomic study. *Anesth Analg* 1995;81:686–93.
20. Grant SA, Nielsen KC, Greengrass RA, et al. Continuous peripheral nerve block for ambulatory surgery. *Reg Anesth Pain Med* 2001;26:209–14.
21. Selander D. Catheter technique in axillary plexus block. Presentation of a new method. *Acta Anaesthesiol Scand* 1977;21:324–9.
22. Klein SM, Grant SA, Greengrass RA, et al. Interscalene brachial plexus block with a continuous catheter insertion system and a disposable infusion pump. *Anesth Analg* 2000;91:1473–8.
23. Salinas FV. Location, location, location: continuous peripheral nerve blocks and stimulating catheters. *Reg Anesth Pain Med* 2003;28:79–82.

24. Borgeat A, Dullenkopf A, Ekatodramis G, et al. Evaluation of the lateral modified approach for continuous interscalene block after shoulder surgery. *Anesthesiology* 2003;99:436–42.
25. Borgeat A, Blumenthal S, Karovic D, et al. Clinical evaluation of a modified posterior anatomical approach to performing the popliteal block. *Reg Anesth Pain Med* 2004;29:290–6.
26. Pham-Dang C, Kick O, Collet T, et al. Continuous peripheral nerve blocks with stimulating catheters. *Reg Anesth Pain Med* 2003;28:83–8.
27. Morin AM, Kranke P, Wulf H, et al. The effect of stimulating versus nonstimulating catheter techniques for continuous regional anesthesia: a semiquantitative systematic review. *Reg Anesth Pain Med* 2010;35:194–9.
28. Fredrickson MJ, Ball CM, Dalgleish AJ, et al. A prospective randomized comparison of ultrasound and neurostimulation as needle end points for interscalene catheter placement. *Anesth Analg* 2009;108:1695–700.
29. Fredrickson MJ, Danesh-Clough TK. Ambulatory continuous femoral analgesia for major knee surgery: a randomised study of ultrasound-guided femoral catheter placement. *Anaesth Intensive Care* 2009;37:758–66.
30. Fredrickson M. “Oblique” needle-probe alignment to facilitate ultrasound-guided femoral catheter placement. *Reg Anesth Pain Med* 2008;33:383–4.
31. Luyet C, Eichenberger U, Greif R, et al. Ultrasound-guided paravertebral puncture and placement of catheters in human cadavers: an imaging study. *Br J Anaesth* 2009;102:534–9.
32. Bloc S, Ecoffey C, Dhonneur G. Controlling needle tip progression during ultrasound-guided regional anesthesia using the hydrolocalization technique. *Reg Anesth Pain Med* 2008;33:382–3.
33. Chin KJ, Perlas A, Chan VW, et al. Needle visualization in ultrasound-guided regional anesthesia: challenges and solutions. *Reg Anesth Pain Med* 2008;33:532–44.
34. Sites BD, Brull R, Chan VW, et al. Artifacts and pitfall errors associated with ultrasound-guided regional anesthesia. Part II: a pictorial approach to understanding and avoidance. *Reg Anesth Pain Med* 2007;32:419–33.
35. Dhir S, Ganapathy S. Comparative evaluation of ultrasound-guided continuous infraclavicular brachial plexus block with stimulating catheter and traditional technique: a prospective-randomized trial. *Acta Anaesthesiol Scand* 2008;52:1158–66.
36. Mariano ER, Loland VJ, Ilfeld BM. Interscalene perineural catheter placement using an ultrasound-guided posterior approach. *Reg Anesth Pain Med* 2009;34:60–3.
37. van Geffen GJ, Gielen M. Ultrasound-guided subgluteal sciatic nerve blocks with stimulating catheters in children: a descriptive study. *Anesth Analg* 2006;103:328–33.
38. Sandhu NS, Capan LM. Ultrasound-guided infraclavicular brachial plexus block. *Br J Anaesth* 2002;89:254–9.
39. Mariano ER, Cheng GS, Choy LP, et al. Electrical stimulation versus ultrasound guidance for popliteal-sciatic perineural catheter insertion: a randomized, controlled trial. *Reg Anesth Pain Med* 2009;34:480–5.
40. Niazi AU, Prasad A, Ramlogan R, et al. Methods to ease placement of stimulating catheters during in-plane ultrasound-guided femoral nerve block. *Reg Anesth Pain Med* 2009;34:380–1.
41. Mariano ER, Loland VJ, Bellars RH, et al. Ultrasound guidance versus electrical stimulation for infraclavicular brachial plexus perineural catheter insertion. *J Ultrasound Med* 2009;28:1211–8.

42. Sites BD, Spence BC, Gallagher JD, et al. Characterizing novice behavior associated with learning ultrasound-guided peripheral regional anesthesia. *Reg Anesth Pain Med* 2007;32:107–15.
43. Koscielniak-Nielsen ZJ, Rasmussen H, Hesselbjerg L. Long-axis ultrasound imaging of the nerves and advancement of perineural catheters under direct vision: a preliminary report of four cases. *Reg Anesth Pain Med* 2008;33:477–82.
44. Wang AZ, Gu L, Zhou QH, et al. Ultrasound-guided continuous femoral nerve block for analgesia after total knee arthroplasty: catheter perpendicular to the nerve versus catheter parallel to the nerve. *Reg Anesth Pain Med* 2010;35:127–31.
45. Tsui BC, Ozelsel TJ. Ultrasound-guided anterior sciatic nerve block using a longitudinal approach: “expanding the view.” *Reg Anesth Pain Med* 2008;33:275–6.
46. Fredrickson MJ. The sensitivity of motor response to needle nerve stimulation during ultrasound guided interscalene catheter placement. *Reg Anesth Pain Med* 2008;33:291–6.
47. Swenson JD, Davis JJ, DeCou JA. A novel approach for assessing catheter position after ultrasound-guided placement of continuous interscalene block. *Anesth Analg* 2008;106:1015–6.
48. Borgeat A, Kalberer F, Jacob H, et al. Patient-controlled interscalene analgesia with ropivacaine 0.2% versus bupivacaine 0.15% after major open shoulder surgery: the effects on hand motor function. *Anesth Analg* 2001;92:218–23.
49. Casati A, Borghi B, Fanelli G, et al. Interscalene brachial plexus anesthesia and analgesia for open shoulder surgery: a randomized, double-blinded comparison between levobupivacaine and ropivacaine. *Anesth Analg* 2003;96:253–9.
50. Ilfeld BM, Moeller LK, Mariano ER, et al. Continuous peripheral nerve blocks: is local anesthetic dose the only factor, or do concentration and volume influence infusion effects as well? *Anesthesiology* 2010;112:347–54.
51. Ilfeld BM, Loland VJ, Gerancher JC, et al. The effects of varying local anesthetic concentration and volume on continuous popliteal sciatic nerve blocks: a dual-center, randomized, controlled study. *Anesth Analg* 2008;107:701–7.
52. Ilfeld BM, Le LT, Ramjohn J, et al. The effects of local anesthetic concentration and dose on continuous infraclavicular nerve blocks: a multicenter, randomized, observer-masked, controlled study. *Anesth Analg* 2009;108:345–50.
53. Le LT, Loland VJ, Mariano ER, et al. Effects of local anesthetic concentration and dose on continuous interscalene nerve blocks: a dual-center, randomized, observer-masked, controlled study. *Reg Anesth Pain Med* 2008;33:518–25.
54. Brodner G, Buerkle H, Van Aken H, et al. Postoperative analgesia after knee surgery: a comparison of three different concentrations of ropivacaine for continuous femoral nerve blockade. *Anesth Analg* 2007;105:256–62.
55. Wajima Z, Shitara T, Nakajima Y, et al. Comparison of continuous brachial plexus infusion of butorphanol, mepivacaine and mepivacaine-butorphanol mixtures for postoperative analgesia. *Br J Anaesth* 1995;75:548–51.
56. Wajima Z, Nakajima Y, Kim C, et al. IV compared with brachial plexus infusion of butorphanol for postoperative analgesia. *Br J Anaesth* 1995;74:392–5.
57. Partridge BL. The effects of local anesthetics and epinephrine on rat sciatic nerve blood flow. *Anesthesiology* 1991;75:243–50.
58. Picard PR, Tramer MR, McQuay HJ, et al. Analgesic efficacy of peripheral opioids (all except intra-articular): a qualitative systematic review of randomised controlled trials. *Pain* 1997;72:309–18.

59. Murphy DB, McCartney CJ, Chan VW. Novel analgesic adjuncts for brachial plexus block: a systematic review. *Anesth Analg* 2000;90:1122–8.
60. Capdevila X, Barthelet Y, Biboulet P, et al. Effects of perioperative analgesic technique on the surgical outcome and duration of rehabilitation after major knee surgery. *Anesthesiology* 1999;91:8–15.
61. Singelyn FJ, Gouverneur JM. Extended "three-in-one" block after total knee arthroplasty: continuous versus patient-controlled techniques. *Anesth Analg* 2000;91:176–80.
62. Singelyn FJ, Deyaert M, Joris D, et al. Effects of intravenous patient-controlled analgesia with morphine, continuous epidural analgesia, and continuous three-in-one block on postoperative pain and knee rehabilitation after unilateral total knee arthroplasty. *Anesth Analg* 1998;87:88–92.
63. Singelyn FJ, Vanderelst PE, Gouverneur JM. Extended femoral nerve sheath block after total hip arthroplasty: continuous versus patient-controlled techniques. *Anesth Analg* 2001;92:455–9.
64. Singelyn FJ, Seguy S, Gouverneur JM. Interscalene brachial plexus analgesia after open shoulder surgery: continuous versus patient-controlled infusion. *Anesth Analg* 1999;89:1216–20.
65. Singelyn FJ, Aye F, Gouverneur JM. Continuous popliteal sciatic nerve block: an original technique to provide postoperative analgesia after foot surgery. *Anesth Analg* 1997;84:383–6.
66. Ilfeld BM, Morey TE, Enneking FK. Continuous infraclavicular perineural infusion with clonidine and ropivacaine compared with ropivacaine alone: a randomized, double-blinded, controlled study. *Anesth Analg* 2003;97:706–12.
67. Ilfeld BM, Morey TE, Thannikary LJ, et al. Clonidine added to a continuous interscalene ropivacaine perineural infusion to improve postoperative analgesia: a randomized, double-blind, controlled study. *Anesth Analg* 2005;100:1172–8.
68. Casati A, Vinciguerra F, Cappelleri G, et al. Adding clonidine to the induction bolus and postoperative infusion during continuous femoral nerve block delays recovery of motor function after total knee arthroplasty. *Anesth Analg* 2005;100:866–72.
69. Ilfeld BM, Morey TE, Wright TW, et al. Interscalene perineural ropivacaine infusion: a comparison of two dosing regimens for postoperative analgesia. *Reg Anesth Pain Med* 2004;29:9–16.
70. Ilfeld BM, Morey TE, Enneking FK. Infraclavicular perineural local anesthetic infusion: a comparison of three dosing regimens for postoperative analgesia. *Anesthesiology* 2004;100:395–402.
71. Iskandar H, Rakotondriamihary S, Dixmieras F, et al. Analgesia using continuous axillary block after surgery of severe hand injuries: self-administration versus continuous injection. *Ann Fr Anesth Reanim* 1998;17:1099–103 [in French].
72. Mezzatesta JP, Scott DA, Schweitzer SA, et al. Continuous axillary brachial plexus block for postoperative pain relief. Intermittent bolus versus continuous infusion. *Reg Anesth* 1997;22:357–62.
73. Eledjam JJ, Cuvillon P, Capdevila X, et al. Postoperative analgesia by femoral nerve block with ropivacaine 0.2% after major knee surgery: continuous versus patient-controlled techniques. *Reg Anesth Pain Med* 2002;27:604–11.
74. di Benedetto P, Casati A, Bertini L. Continuous subgluteus sciatic nerve block after orthopedic foot and ankle surgery: comparison of two infusion techniques. *Reg Anesth Pain Med* 2002;27:168–72.
75. Ilfeld BM, Thannikary LJ, Morey TE, et al. Popliteal sciatic perineural local anesthetic infusion: a comparison of three dosing regimens for postoperative analgesia. *Anesthesiology* 2004;101:970–7.



76. Ilfeld BM, Enneking FK. A portable mechanical pump providing over four days of patient-controlled analgesia by perineural infusion at home. *Reg Anesth Pain Med* 2002;27:100–4.
77. Mariano ER, Loland VJ, Sandhu NS, et al. Ultrasound guidance versus electrical stimulation for femoral perineural catheter insertion. *J Ultrasound Med* 2009;28:1453–60.
78. Mariano ER, Loland VJ, Sandhu NS, et al. A trainee-based randomized comparison of stimulating interscalene perineural catheters with a new technique using ultrasound guidance alone. *J Ultrasound Med* 2010;29:329–36.
79. Ilfeld BM, Morey TE, Enneking FK. The delivery rate accuracy of portable infusion pumps used for continuous regional analgesia. *Anesth Analg* 2002;95:1331–6.
80. Ilfeld BM, Morey TE, Enneking FK. Delivery rate accuracy of portable, bolus-capable infusion pumps used for patient-controlled continuous regional analgesia. *Reg Anesth Pain Med* 2003;28:17–23.
81. Ilfeld BM, Morey TE, Enneking FK. Portable infusion pumps used for continuous regional analgesia: delivery rate accuracy and consistency. *Reg Anesth Pain Med* 2003;28:424–32.
82. Ilfeld BM, Morey TE, Enneking FK. New portable infusion pumps: real advantages or just more of the same in a different package? *Reg Anesth Pain Med* 2004;29:371–6.
83. Klein SM, Nielsen KC, Greengrass RA, et al. Ambulatory discharge after long-acting peripheral nerve blockade: 2382 blocks with ropivacaine. *Anesth Analg* 2002;94:65–70.
84. Williams BA, Kentor ML, Bottegall MT. The incidence of falls at home in patients with perineural femoral catheters: a retrospective summary of a randomized clinical trial. *Anesth Analg* 2007;104:1002.
85. Ilfeld BM, Le LT, Meyer RS, et al. Ambulatory continuous femoral nerve blocks decrease time to discharge readiness after tricompartiment total knee arthroplasty: a randomized, triple-masked, placebo-controlled study. *Anesthesiology* 2008;108:703–13.
86. Ilfeld BM, Mariano ER, Girard PJ, et al. A multicenter, randomized, triple-masked, placebo-controlled trial of the effect of ambulatory continuous femoral nerve blocks on discharge-readiness following total knee arthroplasty in patients on general orthopaedic wards. *Pain* 2010;150:477–84.
87. Ilfeld BM, Ball ST, Gearen PF, et al. Ambulatory continuous posterior lumbar plexus nerve blocks after hip arthroplasty: a dual-center, randomized, triple-masked, placebo-controlled trial. *Anesthesiology* 2008;109:491–501.
88. Ilfeld BM, Esener DE, Morey TE, et al. Ambulatory perineural infusion: the patients' perspective. *Reg Anesth Pain Med* 2003;28:418–23.
89. Ilfeld BM, Morey TE, Enneking FK. Continuous infraclavicular brachial plexus block for postoperative pain control at home: a randomized, double-blinded, placebo-controlled study. *Anesthesiology* 2002;96:1297–304.
90. Ilfeld BM, Morey TE, Wright TW, et al. Continuous interscalene brachial plexus block for postoperative pain control at home: a randomized, double-blinded, placebo-controlled study. *Anesth Analg* 2003;96:1089–95.
91. Ilfeld BM, Vandenborne K, Duncan PW, et al. Ambulatory continuous interscalene nerve blocks decrease the time to discharge readiness after total shoulder arthroplasty: a randomized, triple-masked, placebo-controlled study. *Anesthesiology* 2006;105:999–1007.

92. Ilfeld BM, Morey TE, Wang RD, et al. Continuous popliteal sciatic nerve block for postoperative pain control at home: a randomized, double-blinded, placebo-controlled study. *Anesthesiology* 2002;97:959–65.
93. White PF, Issioui T, Skrivaneck GD, et al. The use of a continuous popliteal sciatic nerve block after surgery involving the foot and ankle: does it improve the quality of recovery? *Anesth Analg* 2003;97:1303–9.
94. Ganapathy S, Wasserman RA, Watson JT, et al. Modified continuous femoral three-in-one block for postoperative pain after total knee arthroplasty. *Anesth Analg* 1999;89:1197–202.
95. Hirst GC, Lang SA, Dust WN, et al. Femoral nerve block. Single injection versus continuous infusion for total knee arthroplasty. *Reg Anesth* 1996;21:292–7.
96. Watson MW, Mitra D, McLintock T, et al. Continuous versus single-injection lumbar plexus blocks: comparison of the effects on morphine use and early recovery after total knee arthroplasty. *Reg Anesth Pain Med* 2005;30:541–7.
97. Borgeat A, Schappi B, Biasca N, et al. Patient-controlled analgesia after major shoulder surgery: patient-controlled interscalene analgesia versus patient-controlled analgesia. *Anesthesiology* 1997;87:1343–7.
98. Capdevila X, Dadure C, Bringuier S, et al. Effect of patient-controlled perineural analgesia on rehabilitation and pain after ambulatory orthopedic surgery: a multicenter randomized trial. *Anesthesiology* 2006;105:566–73.
99. Ilfeld BM, Wright TW, Enneking FK, et al. Joint range of motion after total shoulder arthroplasty with and without a continuous interscalene nerve block: a retrospective, case-control study. *Reg Anesth Pain Med* 2005;30:429–33.
100. Salinas FV, Liu SS, Mulroy MF. The effect of single-injection femoral nerve block versus continuous femoral nerve block after total knee arthroplasty on hospital length of stay and long-term functional recovery within an established clinical pathway. *Anesth Analg* 2006;102:1234–9.
101. Ilfeld BM, Wright TW, Enneking FK, et al. Total shoulder arthroplasty as an outpatient procedure using ambulatory perineural local anesthetic infusion: a pilot feasibility study. *Anesth Analg* 2005;101:1319–22.
102. Ilfeld BM, Gearen PF, Enneking FK, et al. Total hip arthroplasty as an overnight-stay procedure using an ambulatory continuous psoas compartment nerve block: a prospective feasibility study. *Reg Anesth Pain Med* 2006;31:113–8.
103. Ilfeld BM, Mariano ER, Williams BA, et al. Hospitalization costs of total knee arthroplasty with a continuous femoral nerve block provided only in the hospital versus on an ambulatory basis: a retrospective, case-control, cost-minimization analysis. *Reg Anesth Pain Med* 2007;32:46–54.
104. Martin F, Martinez V, Mazoit JX, et al. Antiinflammatory effect of peripheral nerve blocks after knee surgery: clinical and biologic evaluation. *Anesthesiology* 2008;109:484–90.
105. Ilfeld BM, Meyer RS, Le LT, et al. Health-related quality of life after tricompartiment knee arthroplasty with and without an extended-duration continuous femoral nerve block: a prospective, 1-year follow-up of a randomized, triple-masked, placebo-controlled study. *Anesth Analg* 2009;108:1320–5.
106. Bost JE, Williams BA, Bottegall MT, et al. The 8-item Short-Form Health Survey and the physical comfort composite score of the quality of recovery 40-item scale provide the most responsive assessments of pain, physical function, and mental function during the first 4 days after ambulatory knee surgery with regional anesthesia. *Anesth Analg* 2007;105:1693–700.
107. Capdevila X, Pirat P, Bringuier S, et al. Continuous peripheral nerve blocks in hospital wards after orthopedic surgery: a multicenter prospective analysis of

- the quality of postoperative analgesia and complications in 1,416 patients. *Anesthesiology* 2005;103:1035–45.
108. Borgeat A, Ekatodramis G, Dumont C. An evaluation of the infraclavicular block via a modified approach of the Raj technique. *Anesth Analg* 2001;93:436–41.
  109. Nielsen KC, Guller U, Steele SM, et al. Influence of obesity on surgical regional anesthesia in the ambulatory setting: an analysis of 9,038 blocks. *Anesthesiology* 2005;102:181–7.
  110. Coleman MM, Chan VW. Continuous interscalene brachial plexus block. *Can J Anaesth* 1999;46:209–14.
  111. Klein SM, Nielsen KC, Buckenmaier CC III, et al. 2-octyl cyanoacrylate glue for the fixation of continuous peripheral nerve catheters. *Anesthesiology* 2003;98:590–1.
  112. Ang ET, Lassale B, Goldfarb G. Continuous axillary brachial plexus block—a clinical and anatomical study. *Anesth Analg* 1984;63:680–4.
  113. Borgeat A, Ekatodramis G, Kalberer F, et al. Acute and nonacute complications associated with interscalene block and shoulder surgery: a prospective study. *Anesthesiology* 2001;95:875–80.
  114. Boezaart AP, de Beer JF, Nell ML. Early experience with continuous cervical paravertebral block using a stimulating catheter. *Reg Anesth Pain Med* 2003;28:406–13.
  115. Weller RS, Gerancher JC, Crews JC, et al. Extensive retroperitoneal hematoma without neurologic deficit in two patients who underwent lumbar plexus block and were later anticoagulated. *Anesthesiology* 2003;98:581–5.
  116. Klein SM, D'Ercole F, Greengrass RA, et al. Enoxaparin associated with psoas hematoma and lumbar plexopathy after lumbar plexus block. *Anesthesiology* 1997;87:1576–9.
  117. Chelly JE, Greger JR, Casati A, et al. What has happened to evidence-based medicine? *Anesthesiology* 2003;99:1028–9.
  118. Horlocker TT, Wedel DJ, Benzon H, et al. Regional anesthesia in the anticoagulated patient: defining the risks (the second ASRA Consensus Conference on Neuraxial Anesthesia and Anticoagulation). *Reg Anesth Pain Med* 2003;28:172–97.
  119. Horlocker TT, Wedel DJ, Rowlingson JC, et al. Regional anesthesia in the patient receiving antithrombotic or thrombolytic therapy: American Society of Regional Anesthesia and Pain Medicine Evidence-Based Guidelines (Third Edition). *Reg Anesth Pain Med* 2010;35:64–101.
  120. Tuominen M, Pitkanen M, Rosenberg PH. Postoperative pain relief and bupivacaine plasma levels during continuous interscalene brachial plexus block. *Acta Anaesthesiol Scand* 1987;31:276–8.
  121. Bergman BD, Hebl JR, Kent J, et al. Neurologic complications of 405 consecutive continuous axillary catheters. *Anesth Analg* 2003;96:247–52.
  122. Bleckner LL, Bina S, Kwon KH, et al. Serum ropivacaine concentrations and systemic local anesthetic toxicity in trauma patients receiving long-term continuous peripheral nerve block catheters. *Anesth Analg* 2010;110:630–4.
  123. Chelly JE, Greger J, Gebhard R. Ambulatory continuous perineural infusion: are we ready? [letter; comment]. *Anesthesiology* 2000;93:581–2.
  124. Al Nasser B, Palacios JL. Femoral nerve injury complicating continuous psoas compartment block. *Reg Anesth Pain Med* 2004;29:361–3.
  125. Horlocker TT, O'Driscoll SW, Dinapoli RP. Recurring brachial plexus neuropathy in a diabetic patient after shoulder surgery and continuous interscalene block. *Anesth Analg* 2000;91:688–90.

126. Cuvillon P, Ripart J, Lalourcey L, et al. The continuous femoral nerve block catheter for postoperative analgesia: bacterial colonization, infectious rate and adverse effects. *Anesth Analg* 2001;93:1045–9.
127. Gaumann DM, Lennon RL, Wedel DJ. Continuous axillary block for postoperative pain management. *Reg Anesth Pain Med* 1988;13:77–82.
128. Adam F, Jaziri S, Chauvin M. Psoas abscess complicating femoral nerve block catheter. *Anesthesiology* 2003;99:230–1.
129. Cook LB. Unsuspected extradural catheterization in an interscalene block. *Br J Anaesth* 1991;67:473–5.
130. Mahoudeau G, Gaertner E, Launoy A, et al. Interscalenic block: accidental catheterization of the epidural space. *Ann Fr Anesth Reanim* 1995;14:438–41 [in French].
131. De Biasi P, Lupescu R, Burgun G, et al. Continuous lumbar plexus block: use of radiography to determine catheter tip location. *Reg Anesth Pain Med* 2003;28:135–9.
132. Litz RJ, Vicent O, Wiessner D, et al. Misplacement of a psoas compartment catheter in the subarachnoid space. *Reg Anesth Pain Med* 2004;29:60–4.
133. Souron V, Reiland Y, De Traverse A, et al. Interpleural migration of an interscalene catheter. *Anesth Analg* 2003;97:1200–1.
134. Sardesai AM, Chakrabarti AJ, Denny NM. Lower lobe collapse during continuous interscalene brachial plexus local anesthesia at home. *Reg Anesth Pain Med* 2004;29:65–8.
135. Offerdahl MR, Lennon RL, Horlocker TT. Successful removal of a knotted fascia iliaca catheter: principles of patient positioning for peripheral nerve catheter extraction. *Anesth Analg* 2004;99:1550–2.
136. Motamed C, Bouaziz H, Mercier FJ, et al. Knotting of a femoral catheter. *Reg Anesth* 1997;22:486–7.
137. MacLeod DB, Grant SA, Martin G, et al. Identification of coracoid process for infraclavicular blocks. *Reg Anesth Pain Med* 2003;28:485.
138. Capdevila X, Biboulet P, Morau D, et al. Continuous three-in-one block for postoperative pain after lower limb orthopedic surgery: where do the catheters go? *Anesth Analg* 2002;94:1001–6.
139. Singelyn FJ, Gouverneur JM. Postoperative analgesia after total hip arthroplasty: i.v. PCA with morphine, patient-controlled epidural analgesia, or continuous "3-in-1" block? A prospective evaluation by our acute pain service in more than 1,300 patients. *J Clin Anesth* 1999;11:550–4.
140. Singelyn FJ, Ferrant T, Malisse MF, et al. Effects of intravenous patient-controlled analgesia with morphine, continuous epidural analgesia, and continuous femoral nerve sheath block on rehabilitation after unilateral total-hip arthroplasty. *Reg Anesth Pain Med* 2005;30:452–7.
141. Chin KJ, Chee V. Perforation of a Pajunk stimulating catheter after traction-induced damage. *Reg Anesth Pain Med* 2006;31:389–90.
142. Lee BH, Goucke CR. Shearing of a peripheral nerve catheter. *Anesth Analg* 2000;95:760–1.